

## CHUIRURGIE CARDIAQUE/CARDIAC SURGERY

### BLUNT THORACIC AORTIC INJURY: ADVANCES IN THE ERA OF INNOVATION - A REVIEW (PART III)-

A. Thomas Pezzella, MD+  
Anastasios C. Polimenakos, MD#

+ Contact: A. Thomas Pezzella MD  
Founder/Director International Children's Heart Fund  
17 Shamrock Street - Worcester, MA, USA, 01605  
[atpezzella@hotmail.com](mailto:atpezzella@hotmail.com)

#Anastasios C. Polimenakos, MD  
Assistant Profesor of Surgery  
Rush University Medical College, 1653 West Congress Parkway  
Seven Jones - Chicago, IL, USA 60612. - e-mail: [anapolis@aol.com](mailto:anapolis@aol.com)

#### Open Surgical Management

Patients with unstable injuries generally fall into 2 categories: unstable related to the BTAI, with no major associated injuries; and unstable related to associated injuries. Age and comorbidity variables are common to both groups. These patients can remain unchanged or change from unstable to stable and visa versa.

It must be stressed that unstable intraabdominal injuries have surgical priority. Tatou et al.<sup>115</sup> noted 29.9% of patients had concomitant non-aortic surgery. 21.3% had prior surgery, and 8.6% following urgent aortic surgery. Associated cardiac injuries require intra-operative surveillance with TEE. TEE during non- aortic surgery is helpful in ruling out primary cardiac causes for hypotension. Even though the incidence of cardiac injuries is <9%, concern remains. Shapiro et al.<sup>131</sup> noted an incidence of 26% cardiac contusion in a group of blunt thoracic injury.

Preoperative aspects have been noted. Additional preparation for open surgery includes tetanus and antibiotic prophylaxis. Intraoperative concerns include proper positioning, ready availability of blood and blood products, and proper warming capability.

The role of anesthesia is important. Either a left sided double lumen tube or bronchial blocker is utilized. If already intubated, conversion to a double lumen endotracheal tube may be difficult

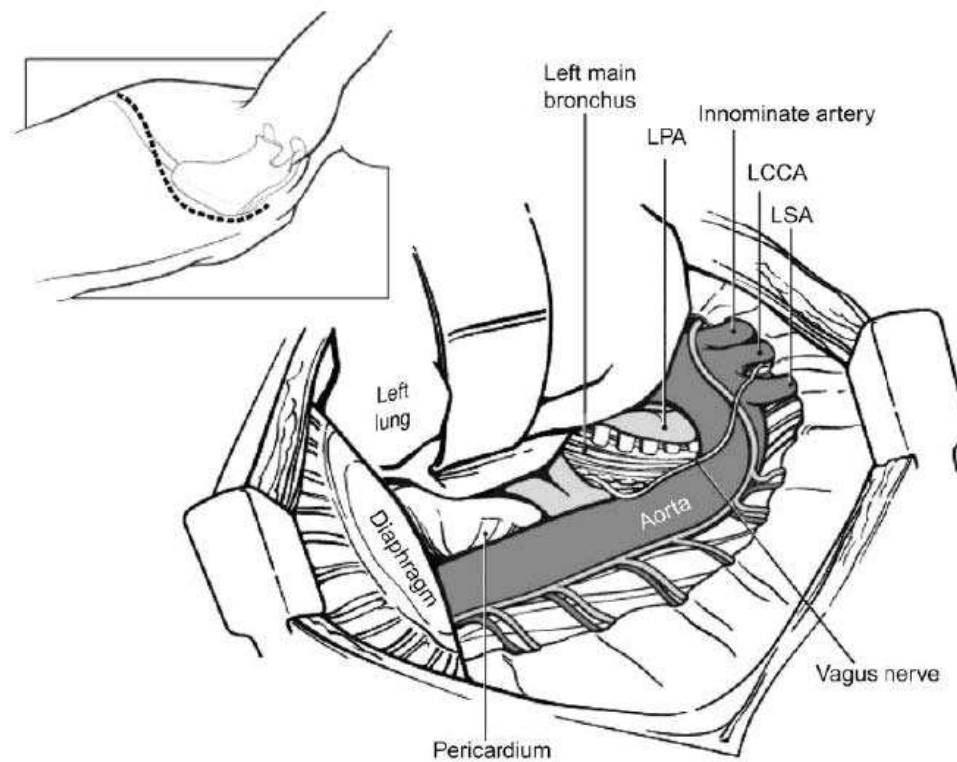
or hazardous. Team communication and cooperation are crucial. Monitoring with ECG, ETcO<sub>2</sub>, arterial and venous pressures, temperature, along with TEE and cerebral oxygen saturation availability are essential. Concomitant continuous upper and lower arterial pressure monitoring in the right radial artery and right femoral artery is important. It is critical to avoid hypertension with aortic cross clamping. This can have an adverse effect on myocardial function secondary to increased afterload. Conversely hypotension can cause decreased collateral flow to the spine. Either hypotension or "paradoxical hypertension" can occur with cross clamp release.

Cannulation of the right femoral vein with a large bore introducer allows high volume infusion of cell saver washed red blood cells. Heating blankets and Bair Huggers are useful adjuncts to reverse hypothermia, especially during the warming phase. Normothermia is critical in reversing coagulopathy. Over-resuscitation with fluids should be avoided<sup>107</sup>.

Hemodynamic changes during surgery may reflect volume sequestration or cardiac function changes. Intra-abdominal bleeding, retroperitoneal hemorrhage, cardiac contusion and tamponade are significant concerns. Progressive hypoxia may be related to left lung collapse, right lung pneumothorax, bleeding or callapse, or progressive ARDS. Caution is



Fig. 24 From Meridith et al p. 101 (103).



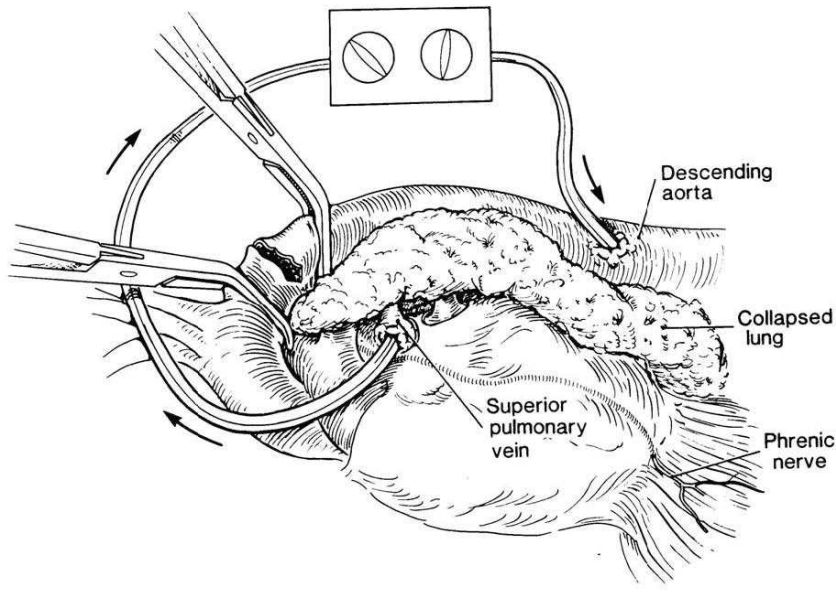
Left posterolateral thoracotomy. A left posterolateral thoracotomy (*inset*) provides excellent exposure of the left pulmonary hilum, left lung, proximal left subclavian artery, descending aorta, distal esophagus, and left diaphragm. LCCA, left common carotid artery; LPA, left pulmonary artery; LSA, left subclavian artery.

The proximal aortic cross clamp is placed between the vagus and phrenic nerves and across the aortic arch between the left carotid and the left subclavian arteries (LSCA), since tears usually extend within 1cm of the LSCA. Alternately, the ascending aorta can be approached intrapericardially. Care must be taken not to damage the pulmonary artery beneath the arch. The LSCA is clamped or snared. In older patients the aorta may be calcified and friable. Occasional occlusion of the left carotid may be required. Primary repair may be achieved, but requires deeper suturing posteriorly to incorporate the adventitial layer. In general, the repairs require grafts since the average disruption separation distance ranges from 2-4 cm<sub>s</sub> (figure 28). More commonly, gel impregnated woven Dacron (Vascutek USA, INC., Austin, TX), or collagen coated woven Dacron graft (Hemashield Dacron graft-Meadox Medicals, Oakland, NJ) interposition are used. Anastomosis is accomplished with a running 3-0 or 4-0 polypropylene suture. Only injured intercostal vessels are sacrificed with ligation.

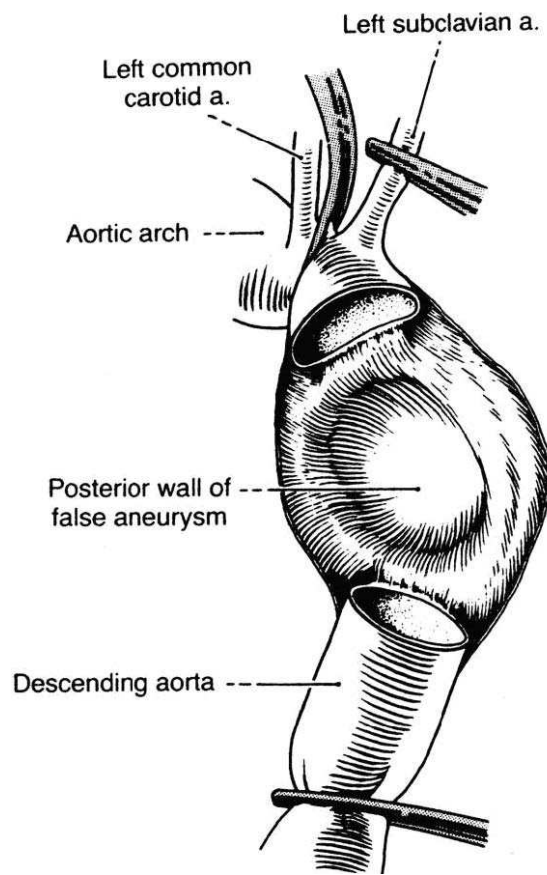
Generally, reimplantation of intercostal vessels are not done. Intraoperative adhesions, difficulties with lung collapse and exposure, as well as

respiratory deterioration, may require conversion from left heart bypass to partial or full cardiopulmonary bypass. The usual perfusion strategy includes left heart bypass without oxygenator and addition of such if needed, along with femoral venous access for conversion to full bypass (figure 30,31). Warming is crucial prior to discontinuation of bypass.

There are 4 approaches to spinal cord protection. These include no protection with clamp and sew; active shunting with partial left heart bypass; a passive Gott shunt; and partial or full cardiopulmonary bypass (CPB) with or without hypothermic circulatory arrest (HCA). An experienced perfusion team is critical in this area.



**Fig. 25\*** : The left superior pulmonary vein and distal descending aorta are cannulated for partial left heart bypass (From Fullerton DA. Simplified technique for left heart bypass to repair aortic transection. *Ann Thorac Surg* 1993;56:579-580.)

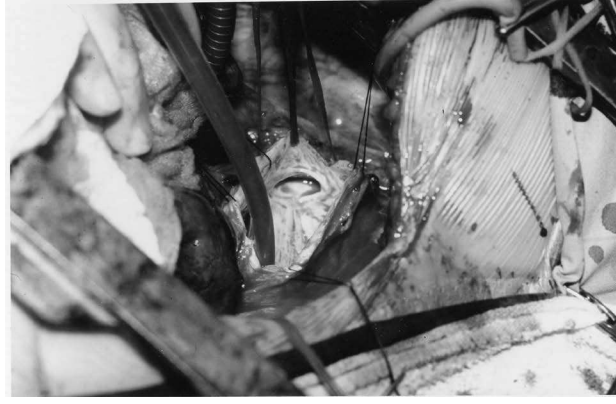

**Fig. 26 :** \* From Symbas PN. *Trauma to the Heart and Great Vessels*. Grune & Stratton, 1978; p.209.

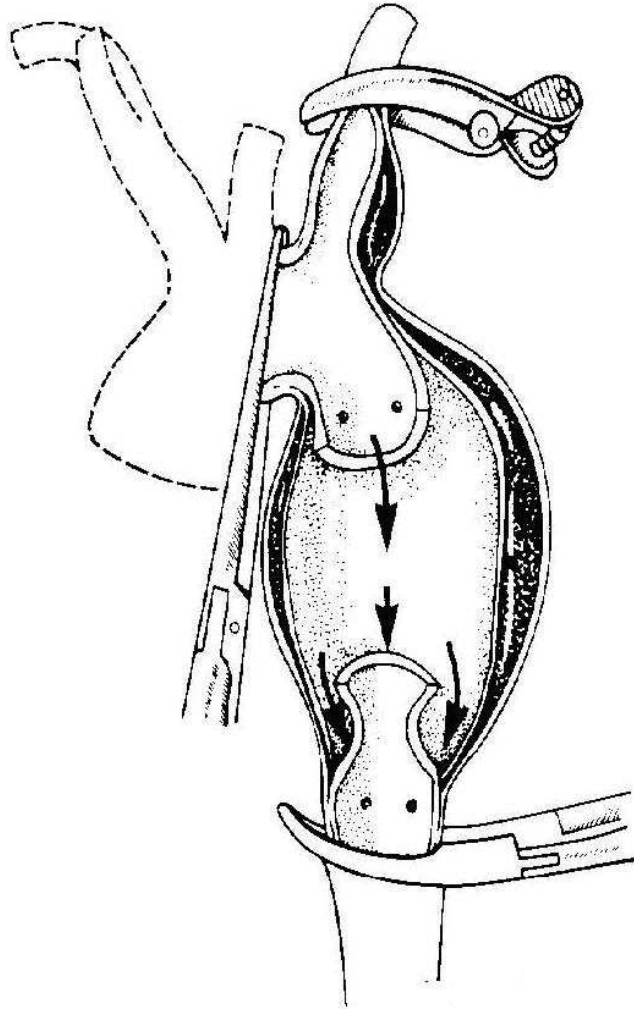
If the clamp and sew technique is utilized, proximal blood pressure control is important, especially after clamping of the proximal aorta. Targeted cross clamps of 30-35 minutes are the optimal goal<sup>142</sup>. Yet an average time of 41 minutes is reported in most series. Cell saver capability (1.5l/mn) is achievable with reinfusion of washed red cells via a large bore femoral or jugular vein access.

With active shunting partial left heart bypass, cannulation of the extra-pericardial left inferior or superior pulmonary vein, rather than cannulating the left atrial appendage is adequate, utilizing a 26-32 french cannula<sup>136,138,144</sup>. This avoids opening the pericardium and cannulating a small, friable or distended left atrial appendage<sup>145</sup>.

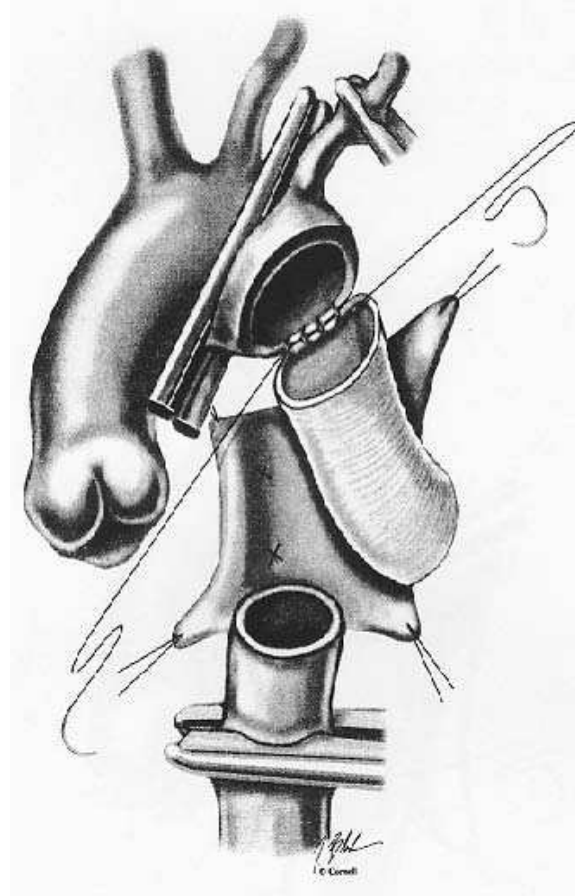
The distal thoracic aorta or left common femoral artery are used, employing a 18-20 french (F) cannula<sup>136,138,144</sup>. Attaching Y arterial connections to the perfusion circuit allow flexibility in changing cannulation sites e.g. transferring the femoral line to distal aorta or vice versa. Targeted distal bypass flows of 2-4L/minute are maintained<sup>138</sup>. Heparin is not necessary, especially if bonded circuits +/- bonded cannulas are used. However, if heparin is used, the doses vary. Gammie et al.<sup>135</sup> used a low mean dose of 73units/kg for left heart bypass, and 300 units/kg for femoral artery/vein bypass. There was no difference in outcome. Heparin helps avoid clotting with stagnation of blood flows <1,000cc/mn<sup>136</sup>. Blood pressure control proximally and distally is critical, with the goal of upper mean aortic mean pressure of 60-70 to maintain cerebral and coronary perfusion, as well as a mean pressure of 50-60 distally to maintain spinal cord perfusion. Flow rates range from 1-4 L/ minute or 1.5 L/min/m<sup>2</sup><sup>16</sup>. Mean pulmonary artery pressure (PAP) is maintained >18-20 to avoid upper body hypoperfusion<sup>16</sup>. Utilization of anesthesia, volume infusion, and vasodilator agents are balanced to maintain targeted flows and pressures.



**Fig. 27 :** Left posterolateral thoracotomy showing opened pseudoaneurysm and proximal aortic orifice (arrow). Suction cannula is in distracted or separated open distal aortic orifice.



**Fig. 28 :** Distracted or separated complete rupture with pseudoaneurysm (From Culliford A. Traumatic Aortic Rupture. In: Hood RM, Boyd AD, Culliford AT.ed. Thoracic Trauma. WB Saunders. Philadelphia. 1989. P. 241.)

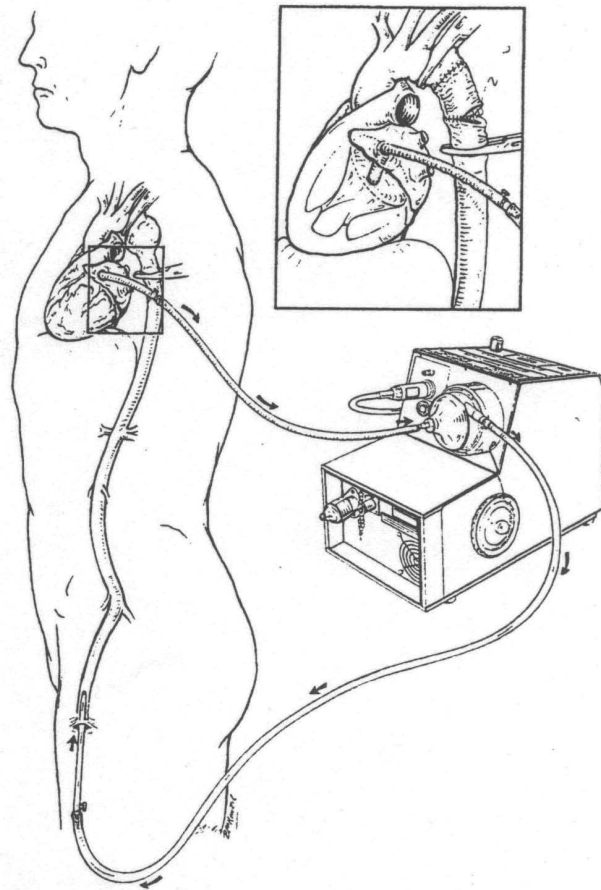


**Fig. 29 :** Graft interposition repair (\* From Girardi LN, Isom OW. Surgery for Acute Aortic Transection. Operative Techniques in Thorac Cardiovasc Surg 1999;4:77-86.)

If passive perfusion with a Gott shunt is utilized, a 9 mm shunt is preferred to the 7.5 mm shunt. With flow meter monitoring, Verdant et al.<sup>46</sup> achieved flows of 1.8 to 4.9 L/min., with an average of 3.05 L/minute. More dissection of the proximal aorta is required for canula placement. Also it offers no advantage in volume loading or inloading, thus making blood pressure control more volatile.

With partial cardiopulmonary bypass (CPB) and heparin coated circuits, ACT's of 150-200 are used if heparin is used, and maintenance of >60mmHg perfusion pressure. Downing et al.<sup>142</sup> reported 50 patients with heparin bonded circuits (? cannulas coated) and no anticoagulation. There was no paraplegia or coagulation problems i.e. thrombosis.

Utilization of cardiopulmonary bypass and hypothermic circulatory arrest may be required for complex cases (figure 31). This is usually decided and planned prior to surgery. Occasionally conversion from left heart to full bypass is necessary. This is especially important where a large pseudoaneurysm precludes safe proximal aortic clamping.



**Fig. 30** (From Szwerz et al. (136) P. 86.). Partial left heart bypass with centrifugal pump. Cannulas are in placed in the left femoral artery by open or percutaneous technique, and left atrial appendage, or left inferior or superior pulmonary vein.

Peltz et al.<sup>141</sup> described their operative approach. Highlights include: access through the left 5<sup>th</sup> posterolateral chest; left femoral and left venous and pulmonary artery for additional return; arrest of the heart with cardioplegia into the cardiopulmonary circuit without aortic cross clamping; and no left ventricular decompression. For ascending aorta or arch injuries Pelz et al.<sup>141</sup> use the median sternotomy approach. Cold blood cardioplegia and left ventricular venting via the right superior are employed. All repairs are delayed in their series in patients with CNS injuries, to minimize the risks of intracerebral bleeding from heparinization. Miller et al.<sup>140</sup> highlighted the advantages of CPB with/without hypothermic circulatory arrest. These included spinal protection, easier control of hemodynamics, volume adjustments with ultra-filtration capability, temperature changes, and blood salvage. Pate et al.<sup>17</sup> adds the advantage of decreasing spinal cord damage by decreasing central venous pressure and increased cerebrospinal fluid pressure, protecting myocardial function, and decreasing time constraints with regards to aortic cross clamp duration. The major disadvantages include increased logistical concerns, fear of

anticoagulation, and the sequelae of systemic inflammatory response syndrome (SIRS).

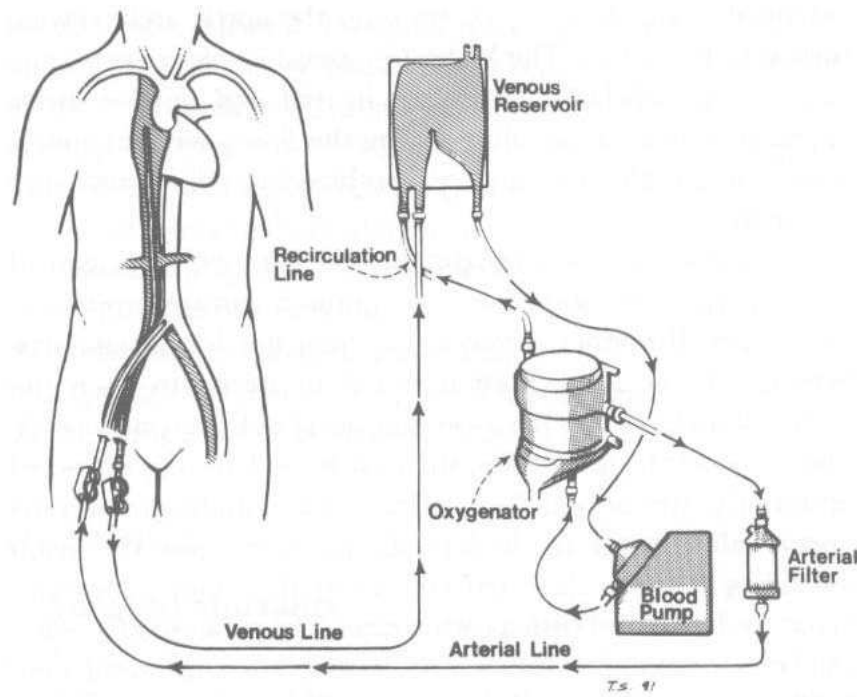
Partial left heart bypass with centrifugal pump. Cannulas are in placed in the left femoral artery by open or percutaneous technique, and left atrial appendage, or left inferior or superior pulmonary vein. Paraplegia or paraparesis following open repair remains a significant problem (table 9)<sup>15</sup>. VonOppell even reported a 2.6% incidence of paraplegia preoperatively<sup>15</sup>. There is consensus that spinal cord protection is the current standard of care, though clamp and sew may be necessary in certain situations, especially when emergency surgery is mandated, and adjunctive methods are unavailable<sup>147</sup>.

**Table 9** : Meta-analysis of Prevalence of New (Postoperative) Paraplegia According to Surgical Technique \*

Descending thoracic aorta	Left posterolateral thoracotomy (4th interspace)
Transverse arch	Median sternotomy with cervical extension
Ascending thoracic aorta	Median sternotomy
Brachiocephalic artery	Median sternotomy with right cervical incision
Right subclavian artery	Median sternotomy with right cervical incision
Left subclavian artery	Median sternotomy with right cervical incision
	Left anterolateral thoracotomy + left supraclavicular incision +/-vertical connecting sternotomy or median

\* Modified from von Oppell and colleagues<sup>15</sup>  
 a Represents 95.7% of 1492 patients reaching operating room in stable condition.  
 b Includes patients with shunting from the ascending aorta and left ventricle.  
 c Includes patients with heparinless partial bypass with centrifugal pump, cardiopulmonary bypass with oxygenator, and heparinless femoral vein to femoral artery bypass without oxygenator.

The anatomy of the spinal artery circulation is important. The basilar artery, along with segmental intercostal and lumbar arteries combine with the anterior spinal artery to supply the spinal cord structures. The anterior spinal artery is incomplete. The lower spine is supplied by the larger arteria radicularis magna or artery of Adamkiewicz<sup>148</sup> (figure 32,33). This artery arises from the T9 (9<sup>th</sup> thoracic vertebral level) to T12 level in 75% of individuals<sup>16</sup>. Aortic cross clamping distal to the origin poses a small risk for spinal cord injury vs. clamping above the origin<sup>16</sup>. Brewer et al<sup>149</sup> documented the segmental perfusion of the spinal cord. There is no continuous uninterrupted flow from the vertebral to lumbar region. Preservation of flow in this important artery is crucial



**Fig. 31 :** Femoral artery/ femoral vein partial cardiopulmonary bypass. Femoral access is either percutaneous or open technique. The venous cannula is advanced to the right atrium under TEE guidance. This partial CPB technique allows oxygenation, cooling/warming, ultrafiltration, and HCA. If left chest approach, then left femoral access. (From Turney (133) P. 211.)

to lower spinal cord protection from T5 to T8. The proximal spinal cord is also important. Collaterals from the LSCA, including the left internal mammary, vertebral, and subscapular vessels also provide spinal cord perfusion<sup>6</sup>.

Intraoperative monitoring of sensory and motor evoked potentials have not proven to be satisfactory for early detection of cord ischemia in traumatic injuries<sup>150</sup>. Yet Cunningham et al.<sup>151</sup>, in 1987, in a series of animal and human studies utilizing sensory and motor evoked potentials, concluded that simple aortic cross-clamping, perfusion pressure <60mmHg, and inability to reimplant critical intercostal vessels resulted in a high percentage of paraplegia. Katz et al.<sup>152</sup> demonstrated a 30 minute safe limit for the "clamp and sew" technique (figure 34). This has been challenged, but remains a safe guideline (figure 35). In the setting of emergency operation, and/or unavailability of adjunctive support, this may be the only option. It must be stressed that the level of aortic crossclamping is important with regards to paraplegia. The incidence of paraplegia rises from 10% 60 minute clamping at the diaphragm level to 80% 60 minute clamping at the isthmus<sup>16</sup>. This may even be higher if the clamp is applied between the left carotid and left subclavian artery, given that the left subclavian artery gives rise to the left vertebral artery, which joins the right vertebral artery to form the anterior spinal artery (figure 32)<sup>16</sup>.

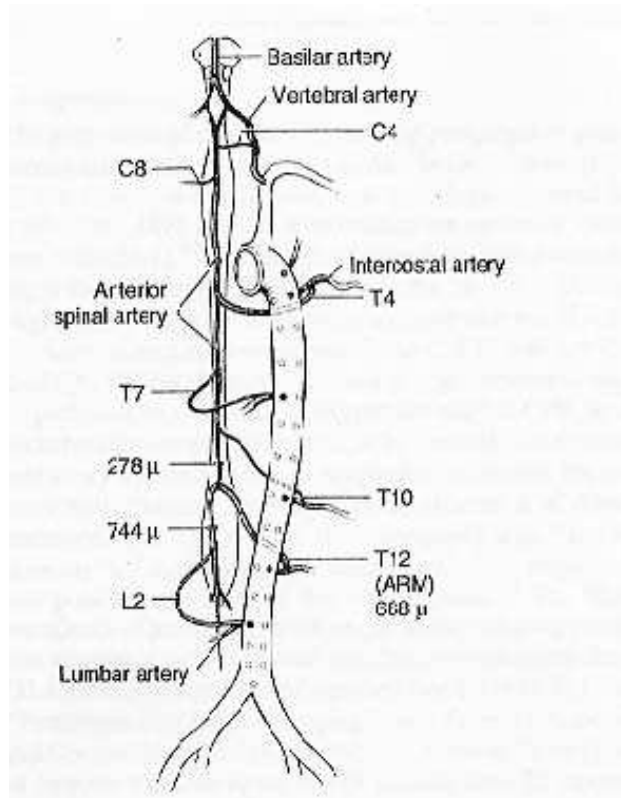
Full CPB using femoral artery and venous

cannulation; partial left heart bypass (PLHB); aorto-aortic heparin-coated passive shunt (9mm TDAMC Gott shunt); and simple "clamp and sew" technique have all been advocated. Antegrade cerebral perfusion and hypothermia with circulatory arrest have been exercised in selected cases (where there is ascending aorta and arch involvement)<sup>48,119,123</sup>.

Although "clamp and sew" technique provides a reliable alternative and can be performed expeditiously by experienced surgeons, optimal exposure and in non-complex injuries<sup>147</sup>, partial left heart bypass gained popularity especially after the initial experience of Olivier et al.<sup>134</sup> from Allegheny Hospital in Pittsburg, and the classic metaanalysis study by vonOppel et al.<sup>15</sup>, in which they reported that simple aortic cross-clamping was associated with a paraplegia rate of 19.2 %; passive shunts with 11.1 %; and active shunt partial left heart bypass only

2.3 % (table 9). From the same metaanalysis, the authors advocated the use of partial bypass with a centrifugal pump and a heparin coated circuit. Only for cross-clamp time less than 30 minutes, can paraplegia be decreased or avoided<sup>47,48,153</sup>. With respect to spinal cord protective adjuncts, certain technical parameters should be taken into consideration such as :

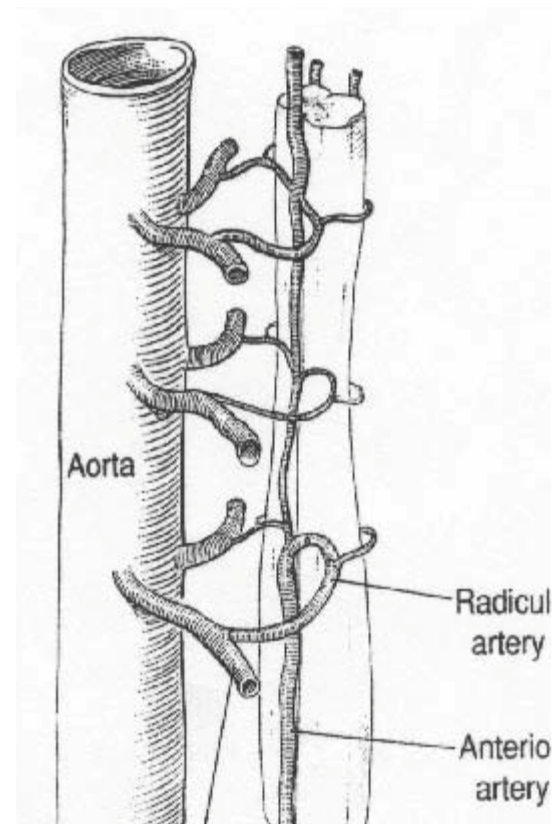
- 1) the duration of cross-clamp time;
- 2) the core body temperature;
- 3) the level of aortic cross-clamp and the quality of the aortic wall;
- 4) the variability in blood supply of the spinal cord and the role of collateral circulation;
- 5) the intra-spinal pressure;
- 6) any associated peripheral vascular disease and the effect in adequate tissue perfusion;
- 7) the intraoperative hemodynamic status of the patient, evidence of shock, hypoxia or hypo-osmolality from fluid overload;
- 8) age;
- and 9) the nature of the case (emergent vs elective)<sup>119,153</sup>. Due to multifactorial etiology of spinal cord ischemia utilized techniques have, often, a variable effect in cerebral and spinal neuroprotection<sup>154</sup>.



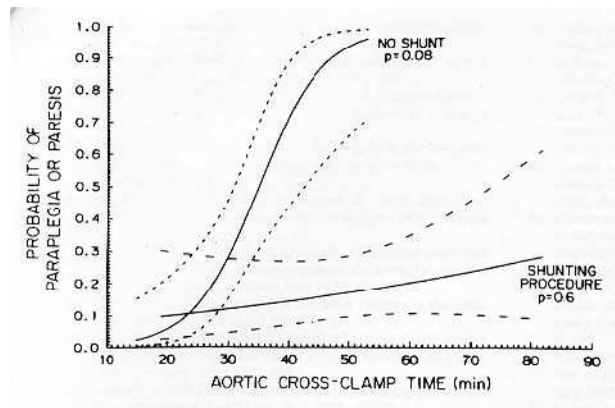
**Fig. 32 :** Summary of findings of the blood supply to the spinal cord in eight human cadaver dissections. Sizes are mean sizes for these arteries when distended under pressure with blood. Level of origin of the arteries may vary in any one person; however, the diagram summarizes the most commonly identifies sites of origin. ( From Svensson LG, Crawford ES. Aortic dissection and aortic aneurism surgery: Clinical observations, experimental investigations, and statistical analyses. Part III. *Curr Probl Surg* 1993;30:1-172.)

Reported adjuncts include core body hypothermia, CSF pressure monitoring and drainage, reimplantation of intercostals, regional hypothermia with epidural cooling, monitoring of somatosensory and motor evoked potentials and other pharmaceutical neuroprotective agents e.g. naloxone, thiopental, steroids, calcium antagonists, free-radical scavengers, papaverine, insulin, magnesium, lidocaine<sup>6,16,125,155-159</sup>. It should be kept in mind that postoperative paraplegia or paraparesis may occur early, or appear 1-3 days later. This may be related to spinal cord ischemia and increasing edema with development of a compartment syndrome. Spinal cord pressure monitoring and cerebrospinal fluid drainage may be necessary<sup>157</sup>. Injuries of the ascending aorta and transverse arch usually require a median sternotomy with cervical extension for involvement of the branched vessels. Occasionally, primary repair may be achieved with aortorrhaphy or arteriorrhaphy, with graft (tube, bifurcated, or branched) interposition being used in the majority of cases<sup>160,161</sup>. Isolated aortic branched vessel injury has, generally, been managed successfully without CPB or temporary shunts. If the ascending aorta or the arch are involved, then CPB with antegrade perfusion or hypothermic circulatory

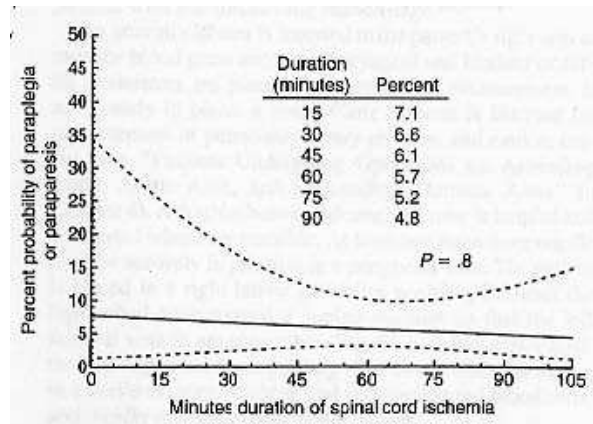
arrest for cerebral neuroprotection is employed. Experience with elective procedures suggest that hypothermic circulatory arrest is well tolerated without detectable sequelae, and safe for up to 45 min duration<sup>159,160</sup>.



**Fig. 33 :** Large radicular artery supplying large segment of anterior spinal cord, usually T5-T8. Results/Complications (\*From Wall MJ, Mattox KL. Thoracic Vascular Complications. In: Mattox KL.ed. Complications of Trauma. Churchill & Livingstone. New York. 1994. P.438.)



**Fig. 34 :** Probability of paraplegia in relation to aortic cross-clamp time with and without lower body perfusion in patients with traumatic aortic rupture at the isthmus ( From (152) Katz NM, Blackstone EH, Kirklin JW, Karp RB: Incremental risk factors for spinal cord injury following operation for acute traumatic aortic transection. *J Thorac Cardiovasc Surg* 1981; 81:669-674.



**Fig. 35 :** From Kouchoukos NT, Blackstone EH, Doty DB, Hanley FL, Kp RB. Kirklin/Barratt-Boyes Cardiac Surgery, 3rd ed Churchill Livingstone. Philadelphia. 2003; p. 1809.

#### Results/Complications

Overall perioperative mortality for BTAI ranges from 10 to 42%<sup>58,59,132,162</sup>. Operative results depends on the patient's overall condition and the anatomic characteristics of the injury (table 10)<sup>15</sup>. The operative skill and experience of the surgeon is difficult to assess. Survival rate can be as low as 50 % if complex ascending or transverse BTAI (involving the brachiocephalic and arch vessels ) is associated with severe closed head injury, cardiac injury, high ISS or severe lung contusion with ARDS. Carter et al.<sup>71</sup> examined anatomical considerations. Lesions <1cm from the inferior border of the LSCA had greater mortality (43%) than lesions >1cm from the border (22%). This highlights the risk of proximal control of the aorta, and warrants consideration of early bypass prior to dissection of the aorta through the periaortic hematoma. Aside from paraparesis and paraplegia, the major post-operative complications include

bleeding, respiratory failure, infection, and complications related to associated injuries, especially, head, abdomen, and extremity injuries. Local causes related to the chest include vagus, phrenic, stellate ganglion, and recurrent nerve injury. Technical related problems include aortic cross clamp injury (especially dissection), pseudo-aneurysm formation, graft infection, graft kinking, or inadequate graft length, and fistula formation to adjacent structures, including esophagus and tracheobronchial tree.

**Table 10 :** Meta-analysis of Patients Reaching Hospital Alive or Operating Room in Stable Condition After Acute Traumatic Transection of Descending Thoracic Aorta (Modified from von Oppell and colleagues<sup>15</sup>)

Descending thoracic aorta	Left posterolateral thoracotomy (4th interspace)
Transverse arch	Median sternotomy with cervical extension
Ascending thoracic aorta	Median sternotomy
Brachiocephalic artery	Median sternotomy with right cervical incision
Right subclavian artery	Median sternotomy with right cervical incision
Left subclavian artery	Median sternotomy with right cervical incision
	Left anterolateral thoracotomy + left supraclavicular incision +/-vertical connecting sternotomy; or median sternotomy with trap door or open book extension along left clavicle

Though spinal cord ischemia and paraplegia is the most devastating complication (with incidence from 2 to 33 %, based on the technique and spinal cord protective adjuncts), these complications remain the unfortunate sequelae for the challenging surgical repair of BTAI<sup>4,6,16,155</sup>. Cowley et al<sup>155</sup> noted more than one major complication in 41 % of those who survived an operative repair of BTAI. Cerebrovascular accidents (CVA), myocardial ischemia, malperfusion syndrome (cerebral, spinal, intestinal, renal ), perianastomotic leak, brachial plexus/vagus nerve/recurrent laryngeal nerve/phrenic nerve injuries, thromboembolic events, pulmonary complications (pneumonia, ARDS), graft infection and sepsis and aortic fistulization are other troublesome complications<sup>132</sup>.

#### Endovascular stent-graft (EVS)

Emerging endovascular solutions have been advocated as a reliable alternative therapeutic option, and it remains to be determined whether surgical treatment priorities in BTAI patients with associated multiple injuries will be a topic of the past (figure 36)<sup>163-182</sup>.