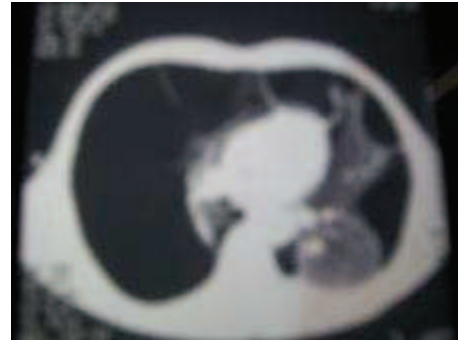

Références

1. Hounkpati A., Bedzra KM., Lawson-Apetoh A., Balogou AA. Pneumothorax : Epidémiologie et prise en charge dans un pays en voie de développement. Rev pneumologie tropicale 2007; 7:16-19
2. Sissoko BF., Diallo S., Sangaré F., Baye O., Pedro GM., et al. Le pneumothorax, étude des aspects épidémiologiques et radio-cliniques Rev Pneumol Trop 2005; 3 :7-10
3. Kayantao D., Sangaré FS., Miriam glorie MG., Diallo S., Sissoko B., et al. Le pneumothorax spontané en milieu spécialisé à Bamako. Med Afr Noire 2002 ; 49 :32-4
4. Levy A., Adam G., Khayat Z., Dupont S., Mornet M. Pneumothorax spontané et tabagisme. Rev Mal Respir 2003 ;20 (1) :1s144
5. Mendez JL., Nadrous HF., Yassallo R., Decker PA., Ryu JA. Pneumothorax in pulmonary langerhans cell histiocytosis: Chest 2004;125:1028-32
6. Guérin JC. Pneumothorax spontané. Rev Prat 1997 ; 47 :1320-1325
7. Touron E., Favez G., Heinzler F. Etude de 54 cas de pneumothorax spontané. Rev Med 1976; 2:151-173
8. Lissac J., Larcen A., Charpin J., Maurice P., Euzéby J., Goulon M., Chrétien J. Pneumothorax spontanés et iatrogènes chez l'adulte : A propos de 217 cas personnels. Bulletin de l'Académie nationale de médecine 1994 ; 2 :213-225
9. Kheloui Y., Lehachi A., Ssaighi O. Le pneumothorax spontané bilatéral simultané. Rev Mal Respir 2003;20(I) :1s145
10. Sayar A., Turnaa A., Metin M., Kucukyagcin N., Solack O., Gurses A. Simultaneous bilateral spontaneous pneumothorax: Repport of 12 cases and review of the literature. Acta chirurgica Belgica 2004;5:572-6
11. Peikert T., Gillespie D., Cassivi S. Cathemential pneumothorax. Mayo Clinic proceedings 2005;80:677-80
12. Michel JL. Le pneumothorax spontané de l'enfant. Arch Pédiatr 2000;7(1) : 39-43
13. Cunnington J. : Spontaneous pneumothorax. In : Clinical evidence. BMJ 2000; 4: 874-79
14. Henry M., Arnold T., Harvey JE.: Guidelines for the management of spontaneous pneumothorax. Standards of Care Committee, British Thoracic Society. Thorax 2003; 58:ii39
15. Andrivet P., Djedaini K., Teboul JL., Brochard L., Dreyfuss D. Spontaneous pneumothorax. Comparison of thoracic drainage versus immediate or delayed needle aspiration. Chest 1995;108:335-9
16. Rodgers BM. Thoracoscopic procedures in children. Semin Ped Surg 1993; 2: 182-9
17. Levi JF., Kleinmann P. Thoracoscopic treatment of pneumothorax: pleural abrasion and pleurectomy. In: Gossot D., Kleinmann P., Levi JF. Surgical thoracoscopy. Paris: Springer-Verlag 1992. 61-69



Iconographie

Figure 1 : Aspect Scanographique d'un pneumothorax sur dystrophie huileuse compressée

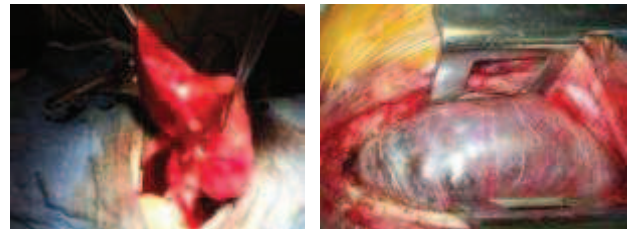


Figure 2 et 3 : Vue Opératoire d'une bulle pulmonaire après une thoracotomie



CHIRURGIE VASCULAIRE / VASCULAR SURGERY

ARTERIAL THROMBOSIS AND LIMB ISCHEMIA FOLLOWING USE OF LEG STOCKINGS DURING AIR TRAVEL: A CASE REPORT.

H NURA ALKALI, B. YAHAYA ADAMU, A. MARTIN AGHAJI, A. SUNDAY BWALA, O. ALIU AKANO.

National Hospital, Abuja, Nigeria

Correspondence : Dr. Nura H. Alkali, FMCP, MSc
Department of Medicine, National Hospital
PMB 425, Garki, Abuja, Nigeria
Email: nalkali@yahoo.com
Tel: + 234 9 6272686
Fax: + 234 9 6272632

Summary

Introduction: Use of leg stockings is recommended for prophylaxis against deep venous thrombosis during air travel. We present a case of arterial thrombosis and limb ischemia following use of leg stockings.

Report: A 55-year old man with vascular risk factors developed ileo-femoral artery thrombosis and lower limb ischemia after a six-hour air flight, during which he applied stockings. Despite intra-arterial streptokinase and embolectomy, he developed foot gangrene.

Discussion: To our knowledge, this is the first report of limb ischemia resulting from use of compression stockings during air travel. Leg stockings may not be safe for passengers with peripheral arterial disease.

Key words: air travel; compression stockings; deep venous thrombosis; peripheral arterial disease.

Résumé

Introduction: On recommande l'utilisation des bas de contention de la jambe pour la prophylaxie contre la thrombose veineuse profonde durant le voyage aérien. Nous présentons un cas d'ischémie de jambe par thrombose artérielle suite à l'utilisation de bas de jambe.

Cas clinique : Un homme âgé de 55 ans, ayant des facteurs de risque vasculaires a développé une ischémie du membre inférieur par thrombose de l'artère ileo-fémorale après un vol de six heures, pendant lequel il a appliqué le bas de contention. Malgré l'administration de la streptokinase intra-artérielle et l'embolectomie, il a développé une gangrène du pied.

Discussion: A notre connaissance, ceci est le premier rapport de l'ischémie de membre résultant de l'utilisation de bas de contention pendant un voyage aérien. Le bas de jambe ne constitue pas une garantie pour les passagers ayant une maladie artérielle périphérique.

Mots clés: Voyage aérien; bas de contention; thrombose profonde veineuse; maladie artérielle périphérique.

Introduction

Use of compression stockings during air travel may prevent deep venous thrombosis amongst high-risk passengers¹. However, it may result in limb ischemia in those with peripheral arterial disease (PAD). We report a case of arterial thrombosis in a middle-aged passenger who used leg stockings, with tragic consequences.

Case report

A 55-year old Englishman presented to the emergency room with pain in his left leg. He had arrived Abuja that morning after a six-hour flight from London, and had applied leg stockings during flight. He was not diabetic or hypertensive, but he took alcohol and had smoked for 40 years.

Past medical history included gout and alcoholic peripheral neuropathy. Two months earlier, he was treated for a right leg cellulitis in the United Kingdom.

Examination revealed a non-tender erythematous right leg. The left leg was pale, cold and tender (figure 1), with absent peripheral pulsations. Sensation was reduced in the right leg and absent in the left.

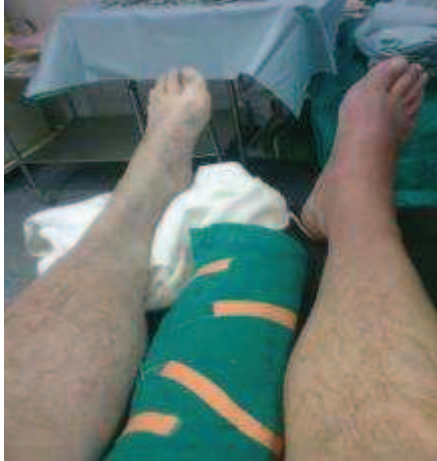

Figure 1: Left lower limb ischemia in a 55-year old man with multiple vascular risk factors who presented to hospital after an air flight. Cellulitis is evident on the right foot.

He was started on Enoxaparin, Clopidogrel, Diclofenac and opiates. A Doppler scan revealed a left femoral artery thrombus causing 65-74% occlusion, but no evidence of deep venous thrombosis. CT angiography showed thrombi and atherosclerotic plaques in the aorta and left ileo-femoral artery above the profunda femoris (figure 2).

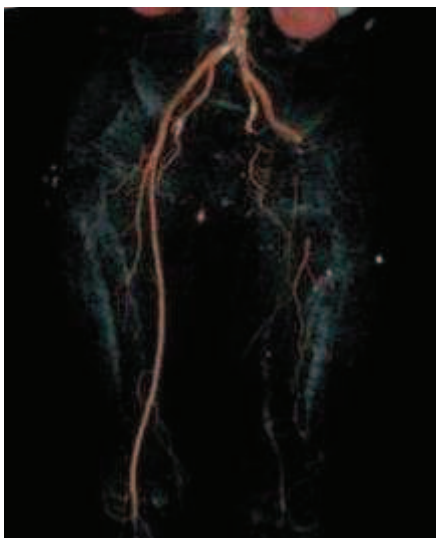


Figure 2: A CT angiogram showing complete obstruction of the left femoral artery. Calcifications and thrombi can be seen in the aorta and common iliac arteries.

He had a femoral artery thrombolectomy and profundoplasty, and was started on Warfarin, Heparin, and Ceftriaxone. Left dorsalis pedis and posterior tibial artery pulsations became palpable. Four days later, there was a re-occlusion of the left popliteal artery, with gangrene of the left heel and big toe. He received three pints of blood and had a popliteal artery embolectomy and intra-arterial streptokinase infusion through a catheter. The next day, he opted for discharge and returned to the UK against medical advice. Two days later, we learned of a below-knee amputation performed at a London hospital.

Discussion

Our patient was a middle-aged man with multiple vascular risk factors. Sadly, his use of leg stockings for prophylaxis against deep venous thrombosis resulted in a limb amputation due to gangrene caused by a recurrent occlusion of the left ileo-femoral artery and its branches.

Deep venous thrombosis (DVT) is a recognized hazard of air travel, forming the basis for the American College of Chest Physicians recommendations for the prophylactic use of anticoagulation or elastic stockings by high-risk, long-distance aircraft passengers². Less well-known is the effect of air travel on the arterial circulation. Teenan and McKay have reported lower limb arterial thrombosis among three air travellers³ and Butcher et al have described two cases of ischemic colitis⁴. While there have been many reports of stroke related to air travel⁵, the consistent association with a patent foramen ovale implicates paradoxical embolism of lower limb DVT, rather than cerebral arterial thrombosis in situ. Our patient had pre-existing PAD, given his vascular risk factors and the findings of atherosclerotic plaques in his aorta and ileo-femoral arteries. Due to his sudden departure, we could not exclude the presence of additional risk factors, such as inherited or acquired thrombophilia. Nonetheless, acute arterial thrombosis was likely precipitated by his use of leg stockings, since he had witnessed many uneventful transcontinental flights in the past, when he did not apply stockings.

To our knowledge, this is the first report of arterial thrombosis related to the use of compression leg stockings during air travel. While compression stockings have been shown to prevent DVT among air travellers¹, the results might not apply to patients with PAD. Further studies are needed to determine the safety of compression stockings among aircraft passengers with risk factors for PAD. In the meantime, clinicians might opt for anticoagulation for DVT prophylaxis in long-distance air travellers with PAD.