



## CHIRURGIE CARDIAQUE / CARDIAC SURGERY

### CALCIFIED PSEUDO-ANEURYSM OF ASCENDING AORTA FROM CANNULATION SITE ERODING INTO THE STERNUM : A CASE REPORT

### PSEUDO-ANÉVRISME CALCIFIÉ DE L'AORTE ASCENDANTE PROVENANT DU SITE DE CANNULATION AORTIQUE AVEC ÉROSION STERNALE : UN CAS CLINIQUE

JALAL JOLOU, CHARUMATHI DASARATHAN, PRASHANT VAIJYANATH, SOMA GUHATHAKURTA, A.THOMAS PEZZELLA, K.M.CHERIAN.

Frontier Lifeline & Dr K M Cherian Heart Foundation

**Correspondence :** Dr. Prashant Vaijyanath, MS, MCh. Sr. Consultant Cardiothoracic Surgeon.  
Frontier Lifeline & Dr K M Cherian Heart Foundation;  
R 30 C Ambattur Industrial Estate Road; Chennai 600 101. India.  
Email: pvaijyanath@hotmail.com  
Tel : 91 44 42017575  
Fax : 01 44 256 5150

---

#### Summary

We report the successful surgical treatment of a nonmycotic pseudoaneurysm of the ascending aorta in a 15 year old male who underwent surgical closure of an atrial septal defect at the age of 3 years. A Computed Tomography (CT) scan was performed to investigate the palpable mass on the healed sternotomy scar. It revealed a densely calcified nonmycotic pseudoaneurysm of the ascending aorta (9.5x 5.5 cm) arising from the prior cannulation site, and eroding into the sternum. Since the aneurysm and the ascending aorta were heavily calcified and adherent to the adjoining structures, it was repaired using a bovine pericardial gusset. The cause of the pseudoaneurysm was considered iatrogenic.

**Key Words:** Pseudoaneurysm, Aortic cannulation site, Congenital Heart Disease, Calcified ascending aorta

---

#### Résumé

Nous rapportons le traitement chirurgical satisfaisant d'un pseudo-anévrisme non mycotique de l'aorte ascendante chez un adolescent de 15 ans qui avait subi la fermeture chirurgicale d'une communication auriculaire à l'âge de 3 ans. Une Tomodensitométrie (TDM) a été prescrite pour examiner la masse palpable sous la cicatrice de sternotomie guérie. Elle a révélé un pseudo-anévrisme non mycotique densément calcifié de l'aorte ascendante (9.5x 5.5 cm) siégeant au site de la cannulation antérieure et accolée à la face interne du sternum. Puisque cet anévrisme de l'aorte ascendante était très calcifié, comprimant et adhérent aux structures contiguës, il a été procédé à une mise à plate-greffe par une prothèse péricardique d'origine bovine. Ce pseudo-anévrisme a été considéré comme d'origine iatrogène.

**Mots clés:** Pseudo-aneurysm, site cannulation Aortic, Cardiopathies congénitales, Calcification aorte ascendante.

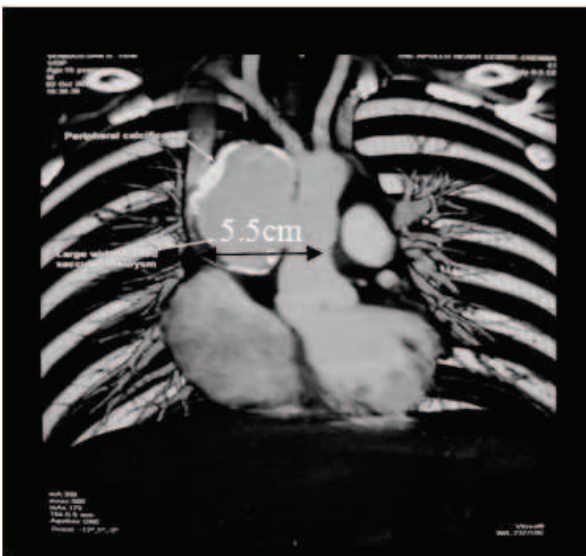## Introduction

A post-operative pseudo-aneurysm of the ascending aorta is a known complication after open heart cardiac surgery, and has been reported to occur in less than 0.5% of cardiac operations and is associated with increased morbidity and mortality<sup>1,6</sup>.

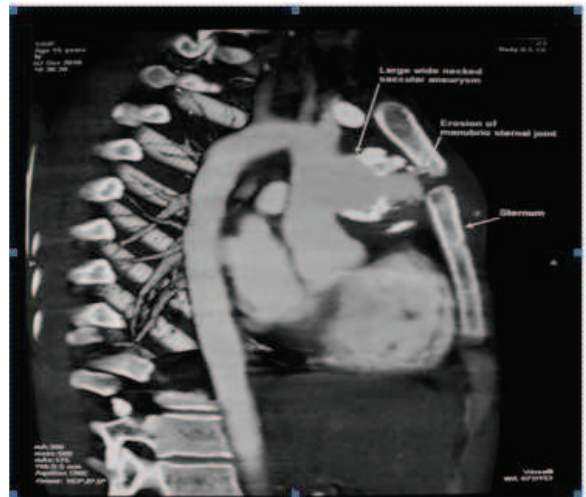
We describe a case of an ascending aortic pseudoaneurysm occurring 12 years after closure of an ASD. The pseudoaneurysm originated from the previous aortic cannulation site.

## Case Report:

A 15 year old male, who underwent operation for atrial septal defect (ASD) at 3 years of age, presented with recent syncopal attacks, swelling, and pain at the sternal wound site for the past two months. Evaluation at our hospital with Computed Tomography (CT) angiography (**Figure 1**), revealed a saccular aneurysm of the ascending aorta (5.5cm in diameter) eroding into the sternum (**Figure 2**).

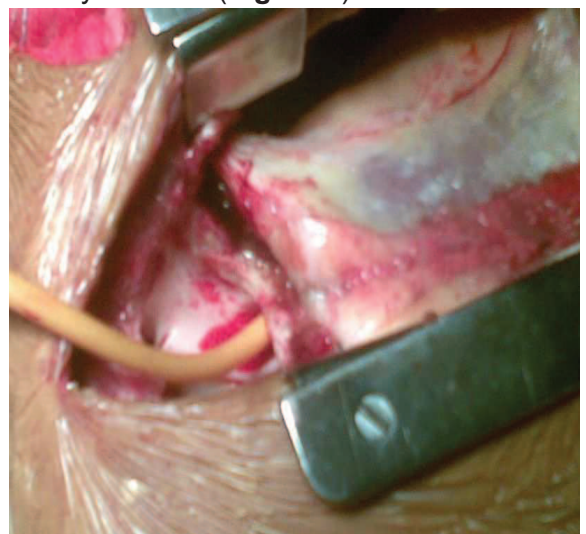

**Figure 1:** Computed Tomography (CT) angiography, coronal view, showing saccular aneurysm of ascending aorta (5.5cm in diameter).



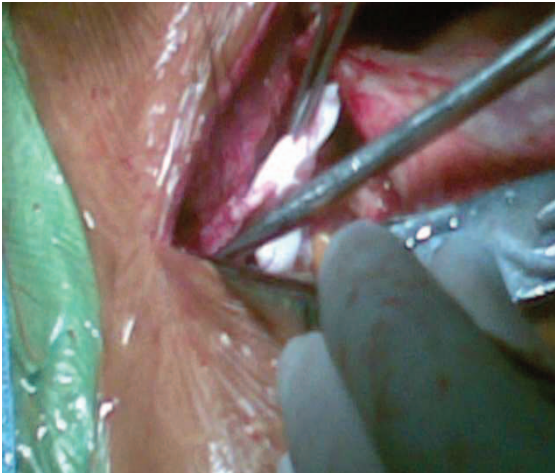
**Figure 2:** Computed Tomography (CT) angiography, sagittal view, showing ascending calcified aortic aneurysm eroding into the sternum.

The operation was performed employing femoro-femoral bypass, with an additional venous cannula placed in the pulmonary artery following redo sternotomy. The apex of the left ventricle was identified by transthoracic echocardiography (TEE) and vented via a small left anterior thoracotomy. Redo-median sternotomy was done, and the patient taken to deep hypothermic circulatory arrest (18 C°). The pseudo-saccular ascending aortic aneurysm was dissected and found to originate at the previous aortic cannulation site, and eroding into the sternum. It was opened, and excised proximally, starting from the sinotubular junction and extending distally to 1 cm below the origin of the innominate artery. The entire aneurysm and the adjacent part of the ascending aorta was heavily calcified. The right coronary artery and aortic valve were not involved. Myocardial protection was maintained with antegrade root cardioplegia delivered via a 16F Foley catheter (**Figure 3**).



**Figure 3:** Intra operative picture showing antegrade root cardioplegia through the aneurysm, delivered through a 16F foley catheter.

The aneurysm was repaired using a 7 X 5 cm decellularised bovine pericardial gusset (**Figure 4**) with # 3-0 Prolene suture (Ethicon,Somerville, NJ).



**Figure 4:** Intra-operative picture showing the aneurysm repair using a 7X5cm decellularised bovine pericardial gusset with #3-0 polypropylene suture.

The patient was slowly rewarmed and weaned off cardiopulmonary bypass without inotropic support. He was extubated on the first post-operative day and had an uneventful recovery, and was discharged on the eighth post-operative day.

## Discussion

Aortic non-mycotic pseudo-aneurysm is a rare complication following open heart surgery. The potential locations include the aortotomy suture line, coronary graft site anastomosis, and cardioplegia or aortic cannula sites. Late presentation is not unusual, having been reported at 26 and 40 years following surgery<sup>4,6</sup>. Once diagnosed, they require urgent surgical intervention to prevent iatrogenic rupture. Employing cardiopulmonary bypass (CPB) via femoral access prior to sternotomy should be considered a viable option in such scenarios. This judgment is made pre-operatively using CT-scan, which has a greater advantage of imaging the surrounding anatomic structures, thus helping to define a surgical strategy.

In this case, the pseudo-aneurysm originated from the previous aortic cannulation site, and extended into the sternum. Since sternal re-entry carried a high risk of fatal hemorrhage, we initiated femoro-femoral CPB, prior to opening the sternum across the aneurysm. Although moderate hypothermia with low flow or deep hypothermic circulatory arrest (DHCA) has been

reported<sup>1</sup>, we preferred a short period (20 minutes) of total circulatory arrest (TCA) to carry out the procedure.

Usually the aneurysmal aorta is replaced by prosthetic grafts or homograft in presence of infection, but in our case, as there was a well defined rent with healthy viable aortic tissue and no evidence of infection, it was repaired using a decellularised bovine pericardial gusset.

## References

- 1- Dumont E., Carrier M., Cartier R., et al. Repair of aortic false aneurysm using deep hypothermia and circulatory arrest. *Ann Thorac Surg* 2004; 78: 117-121
- 2- Ramakantan R., Shah P. False aneurysm secondary to aortic cannulation-rupture into lung with fatal hemoptysis during aortography. *Thorac Cardiovasc Surg* 1989;37:322-323
- 3- Dhadwal AK., Abrol S., Zisbrod Z., Cunningham JN. Jr. Pseudo-aneurysms of the ascending aorta following coronary artery bypass surgery. *J Card Surg* 2006; 21: 221-224
- 4- Nakayama T., Saito T., Asano M., Nomura N., Mishima A. An aneurysm at the cannulation site discovered 40 years after cardiac surgery. *Ann Thorac Cardiovasc Surg* 2008; 14
- 5- Stanger O., Oberwalder P., Dacar D., Knez I., Rigler B. Late dissection of the ascending aorta after previous cardiac surgery: risk presentation, and outcome. *Eur J Cardio-thorac Surg* 2002; 21:453-458
- 6- Murayama H., Watanake T., Kubayashi Y., Matsumura Y., Kokoyashi A. Nonmycotic false aneurysm of aortic cannulation site presenting 26 years postoperatively. *Ann Thorac Surg* 2009; 87: 936-939.