

The CT chest scan confirmed bilateral complicated cysts (**figure 3**).

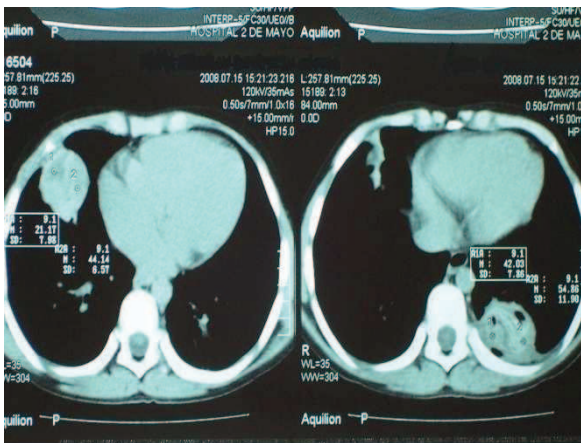


Figure 3: CT scan showing bilateral complicated cysts. Note the aerated areas within the cysts, and no evidence of mediastinal disease.

An abdominal ultrasound was negative for the presence of liver cysts.

With a preoperative diagnosis of bilateral complicated hydatid cysts, and moderate to severe hemoptysis, surgery was recommended. Following one week of preoperative broad spectrum antibiotic and albendazole (10mgs/kg/day) treatment, the patient underwent a right anterior thoracotomy via the 4th intercostal space on July 23, 2008. A single lumen endotracheal tube was employed. The procedure included cystotomy, evacuation of the ruptured laminal membrane, identification and closure of multiple bronchial air leaks with polypropylene suture (Prolene, Ethicon Inc., Somerville, New Jersey, USA), open cavity without capitonnage, and pleural drainage of the apical/anterior and posterior/basal chest cavity with 2 chest tubes and connected to under wáter seal drainage at low suction. The operative findings revealed a complicated and infected hydatid cyst (6 x 6 x 6 cms), localized to the lateral right lower lobe (**figures 4-6**).

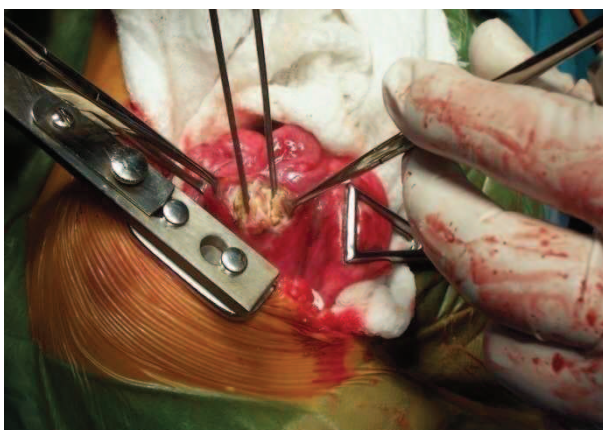


Figure 4: Opened pericyst revealing a ruptured cyst with membranes

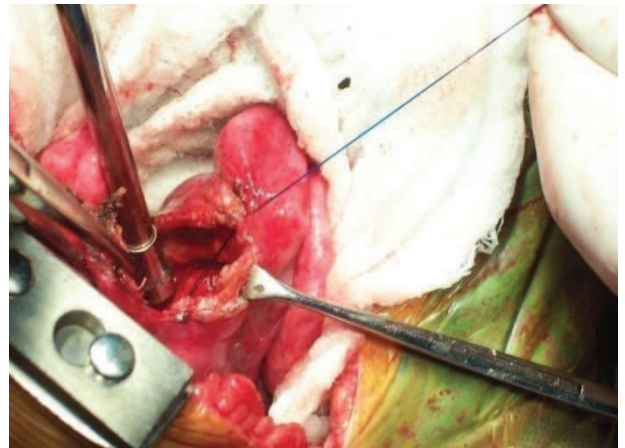


Figure 5: Cyst removed leaving open cavity and surrounding pericycstic wall or adventitia.

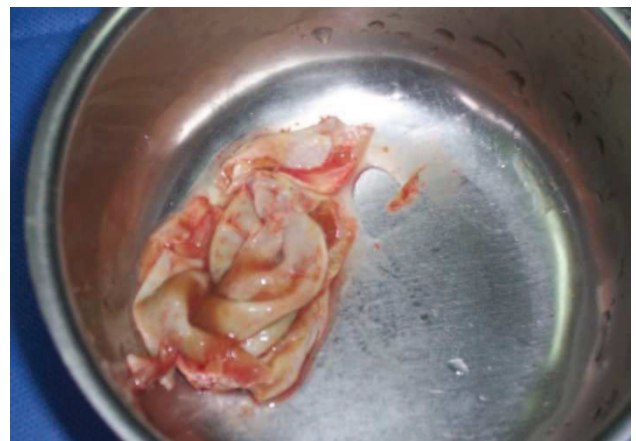

Figure 6: Removed cystic membrane.

Subsequently, during the same hospitalization, and after a satisfactory postoperative course, the second stage operation was performed on August 8, 2008 via a left lateral thoracotomy through the 4th intercostal space. The operation included cystotomy, evacuation of the ruptured lamina membrane, closure of multiple bronchial air leaks with Prolene suture, capitonnage, and pleural drainage with 2 chest tubes, one placed anteroapical, and the other lower posterior. Drainage was applied as first operation. The operative findings revealed dense adhesions of the left lower lobe to the diaphragm and chest wall, The cyst was complicated (6 x 6 x 6 cms), and localized to the mid-left lower lobe (**figure 7- 9**).

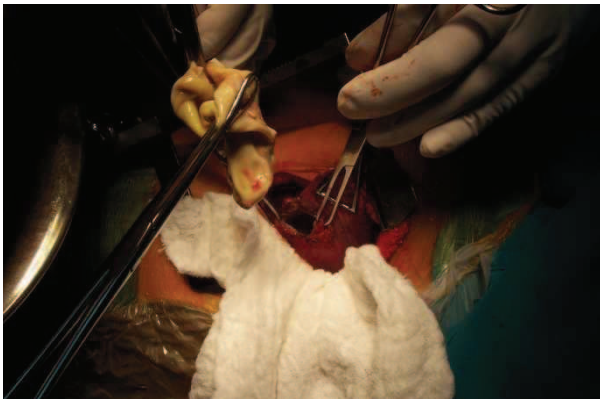


Figure 7: Opened cavity revealing removed ruptured cyst membrane.

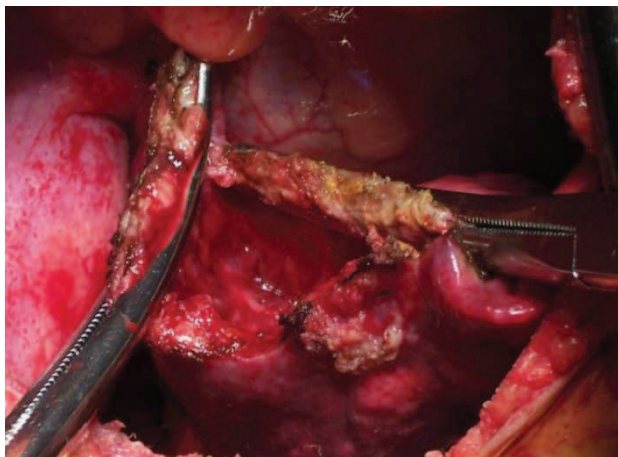


Figure 8: Open cavity with thickened pericyst or adventitial wall. This cavity is cleansed and bronchial fistulae closed with figure of eight suture

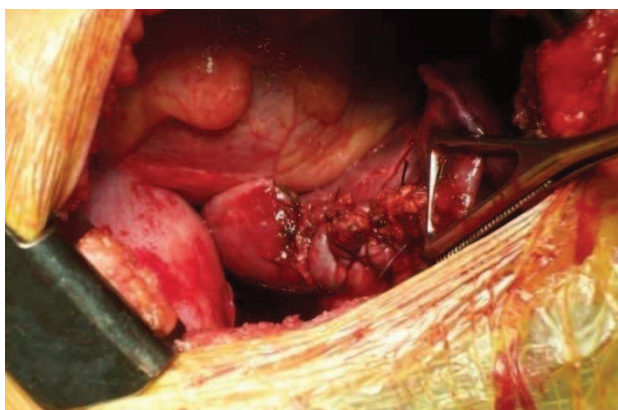


Figure 9: Obliterated cyst utilizing capitonnage method. Cavity is obliterated and the pericyst or adventia layers closed over the end.

The postoperative course was uneventful, and the patient was discharged home on August 16, 2008. Albendazole drug treatment was not continued.

Discussion

A large worldwide surgical experience of hydatid lung cyst disease in children living in endemic countries, especially Turkey, has been reported^{10,16}. In Peru, human hydatid disease, secondary to the parasite *Echinococcus granulosus* (*Taenia echinococcus*) genetic type 1 and 5, is caused by the larval form of the cestode “dog” tapeworm¹. The incidence in Peru is 1.1 per 100,000 population. The incidence is higher in males, and occurs primarily in rural areas of farming and animal domestication. Most infections involve a single cyst. 65% of solitary cysts are found in the liver, with 25% in the lung and the remainder in other organs including kidney, spleen, heart, mediastinum, bone, brain, uterus, fallopian tubes, mesentery, diaphragm, and muscles. In children the ratio of liver to lung is reversed. Approximately 10-15% of lung cysts will have an associated hepatic cyst (<http://en.wikipedia.org/wiki/Echinococcus>). The life cycle is illustrated in **figure 10** (http://en.wikipedia.org/wiki/File:Echinococcus_Life_Cycle.png).

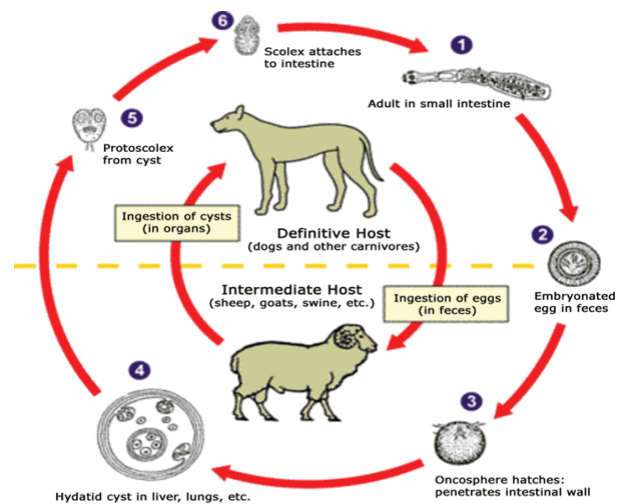


Figure 10: The life cycle.

Echinococcus eggs contain an embryo (oncosphere or hexacanth). These eggs are passed in the feces of the definitive host, and the ingestion of these eggs lead to infection in the intermediate host. The released egg embryo develops a *hydatid cyst*, which can grow to about 5–10 cm within the first year and can survive within organs for years. At a diameter of 1 cm, the wall differentiates into a thick outer, non-cellular laminar membrane that covers the thin inner germinal epithelial layer. From this epithelium, cells begin to grow within the cyst. These cells then become vacuolated (brood capsules), from which protoscolices develop. Daughter cysts also form within these cysts⁴.

The intermediate human host becomes infected, more commonly by direct contact with the definitive dog host, especially contaminated feces, or by ingestion of contaminated water or food, contracts the *Echinococcus* tapeworm eggs that contain the embryo (oncosphere or hexacanth). Sheep are the usual intermediate or secondary hosts. Larval cysts expand slowly over years or decades becoming symptomatic as they enlarge and impinge on local structures. The cysts contain hundreds of viable scoleces that are capable of developing into adult tapeworms upon ingestion by a definitive host, such as the domestic dog. The cysts grow independently. Pressure within the intact cyst ranges from 20-60 cm H₂O, and contains antigens capable of immediate host anaphylaxis². The germinal membrane lining the cyst produces new scoleces on an ongoing basis. Each scolex is capable of becoming a new daughter cyst, either within the original cyst, or elsewhere should the original cyst rupture. The established hydatid lung cyst wall is composed of 3 layers. This includes: the inner germinal layer, the outer laminated layer, and the outer adventitial or pericyst layer which is the host reactive area, and composed of fibrous and compressed inflammatory lung tissue².

Humans become infected, as noted, primarily by ingesting contaminated infected food or water, and rarely by direct contact with infested dogs or domesticated farm animals. There are three mechanisms of lung involvement: hematogenous spread through the liver; lymphatic spread from the thoracic duct to the right heart and then into the lung parenchyma; or direct exposure from egg inhalation⁴.

Most cysts are asymptomatic. Symptoms develop when they become complicated i.e infected or rupture into adjacent structures, most commonly the bronchial tree, or cause compression of adjacent structures. Symptoms are more common in children due to the large expansion and compression of local structures in a fixed thoracic space, given that their lung tissue is more elastic and expansive than restrictive liver tissue. There is also a higher incidence of rupture in about 30% of cases⁵. Common symptoms include fever, dry or productive cough, chest pain, dyspnea, and occasionally hemoptysis with complicated cysts. The expectoration of large amounts of salty fluid, or smaller amounts of ruptured cyst walls ("grape skins") are characteristic of a complicated cyst, and an associated bronchial connection. Rarely, with rupture or erosion of a liver cyst through the diaphragm into the lung a bronchobiliary fistula can develop with resultant expectoration of bile fluid (biloptysis). Ruptured cysts also have a

higher incidence of associated problems, including anaphylaxis, pneumonia, pneumothorax, and empyema. Thoracic deformities and growth retardation have been reported in children, but are extremely rare.

The initial CXR (PA/lateral) is highly suspicious for hydatid cyst disease. The simple cyst is usually a spherical well-defined homogeneous mass or opacity with sharp margins. The size determines the degree of symptoms and associated features that include distal atelectasis or pneumonitis. There are several radiographic findings that are seen, especially with complicated cysts (i.e. ruptured or infected). These are the result of bronchial communication creating air fluid levels. They create a meniscus of air between the pericyst and endocyst. This is called the water lily or crescent sign^{4,6}. The right lower lobe is the most common location. The incidence of solitary cysts is about 60%, and multi unilateral or bilateral cysts range from 20 to 50%. It is important to document the number of cysts present either unilaterally or bilaterally since documentation at surgery can be difficult for the deeper seated or smaller cysts. Associated pneumothorax or empyema can also be present from ruptured complicated hydatid cysts. The presence of air or loculations within the space is confirmatory or suspicious for rupture and/or infection. CT scanning (sensitivity > 90 %) has become routine for surveying both the chest and abdominal cavities. Confirmation of other cysts and the presence of rupture can be confirmed, as well as associated hepatic involvement. The differential diagnosis in children is limited, given that carcinoma, tuberculoma, or congenital cysts are rare or uncommon. Abdominal ultrasound is routinely performed, though the incidence of hepatic cysts is less common in children.

Laboratory tests complement the clinical and radiological findings. Serological testing with IgG ELISA (enzyme-linked immunosorbent assay) (sensitivity 80-99%; specificity > 60%), and immunoelectrophoresis (IEP) (sensitivity > 70%; specificity 100%) are the current recommended laboratory tests^{1,5}. Serology is usually positive with hepatic cysts but sensitivity drops below 50% with solitary pulmonary cysts even when the cyst is large.

Eosinophilia > 5 - 8 % is observed in 20-34% of cases, especially with complicated cysts. An elevated peripheral WBC count is suggestive of infectious contamination of a ruptured cyst. The Casoni skin test, and the Weinberg complement fixation test are no longer utilized³. Serology testing is also helpful in in both early and long-term postoperative surveillance.

Diagnostic bronchoscopy is no longer routinely done or recommended. There is concern that it may provoke bronchial rupture, or worsening hemoptysis when present⁵. However, it may be useful in patients without a diagnosis, especially older children to rule out carcinoma, tuberculoma, or in suspected complicated, ruptured cysts. Therapeutic bronchoscopy has not been well described, but may play a role in massive hemoptysis to isolate the side of bleeding with bilateral cystic disease. Needle thoracentesis may be helpful for evaluation of pleural effusions, especially for a coexistent ruptured cyst with pleural extension.

There is no unified surgical classification of thoracic hydatid cysts regarding definition, size, location, distribution, associated adjacent structure involvement, or definitive guidelines regarding treatment (**Table N°1**)¹⁷.

Table 1 : Surgical classification of thoracic hydatid cysts

localisations	Site	
Intrapulmonary	Complicated cyst (infected/ruptured) vs. Simple cyst (intact)	
	Giant (>10cm)	
	Single lobe, usually lower	
	Single bilateral	
	Unilateral/ Multilateral	
	Multiple cysts: unilateral or bilateral	
Extrapulmonary/ Intrathoracic	Lung location: hilar, mid-lung, or peripheral	
	Pleural extension	
	Local extension from lung:	Bronchus
		Pulmonary artery
		Aorta
		Mediastinum
Extra-thoracic	Pericardium	
	Heart	
	Liver: direct penetration or rupture into thorax, or separate cyst	

Treatment

Medical

Every identified pulmonary hydatid cyst should be treated⁵. However, medical treatment alone is not effective since drugs cannot penetrate the hydatid cyst wall. Drugs are useful in acute therapy situations when cysts rupture (spontaneously or due to surgical mishap) and scoleces are lying free before encysting again. They are also useful in patients who are not candidates for surgery, and as adjunctive therapy perioperatively, especially for complicated contaminated cysts.

The benzimidazole compounds albendazole (ABZ) or mebendazole (MBZ) are the drugs of choice for intact hydatid cysts that are not operable, such as multiple or disseminated, or in non compliant or high risk patients with severe prohibitive comorbidity¹. They are also the adjunctive drugs of choice, when used, for surgery. However, a trial of ABZ may be considered for solitary cysts that are < 10 cm. Response is generally slow and complete in a minority of cases. However, when used, ABZ is preferred, given better GI absorption and higher plasma levels. Reported response rates with chemotherapy alone range from 25-70%^{1,3,5}. With medical treatment alone the recommended dose of ABZ is 400mgs bid x 1-6 months; children-15mg/kg/day for 1-6 weeks.

Surgery is recommended for the majority of solitary cysts, especially in the pediatric population. When surgery is planned, preoperative broad spectrum, or culture proven specific antibiotics, are recommended for proven or suspected complicated cysts.

There is no unified consensus regarding ABZ or MBZ as adjuvant treatment^{11,17}. There is concern that routine pre-operative ABZ may, in fact, increase the risk of operative rupture of intact cysts, secondary to weakening of the cyst wall^{8,9}. Yet there are potential advantages that include: reduction in size, decreased intraluminal pressure, and decreased cyst fertility or growth¹¹. Our approach is to administer ABZ for 7-10 days prior to surgery, or to continue medication previously initiated, as well as appropriate antibiotics if an infected cyst is suspected or confirmed. When used postoperatively, ABZ treatment is continued in cycles of 28 days for 1-3 months, or longer, in doses of 10-14mgs/kg/day with a 14 day rest period between cycles⁵. However, ABZ treatment is individualized, given that non-compliance, and access to drugs may be limiting factors.

Interventional

Puncture-aspiration-injection-reaspiration (PAIR) is an invasive technique used primarily for liver cysts¹. It is not recommended for lung, heart, brain, or spinal disease^{1,5}. In fact, it may be contraindicated, since pneumothorax, development of new cysts, and anaphylaxis are possible complications. Percutaneous thermal ablation has also been advocated, but not for parenchymal lung disease¹.

Surgery

Operative Aspects

Surgery is the treatment of choice for the majority of hydatid cysts in both asymptomatic and symptomatic pediatric patients, since most patients will ultimately become symptomatic and develop complications^{10,16}.

Children develop symptoms with progressive concentric enlargement of cysts and compression of adjacent structures, as well as a higher incidence of rupture. The principle goals of surgery is to remove the involved cyst(s), utilize precautions to prevent cyst rupture and contamination, meticulous closer of all bronchial air leaks, preservation of lung tissue when feasible, especially in children, and prevent recurrence from residual disease or incomplete resection.

Careful planning and timing of surgery, access incisions, exposure, and identification of the involved areas are important. The cysts are usually classified as superficial or deep, and simple (intact) or complicated (i.e. ruptured and/or infected) (Table N^o1). The latter is usually diagnosed on the preoperative CXR and thoracic CT scan, but sometimes it is confirmed only at operation. A variety of scenarios can occur with regard to the extent of disease (**figure 11**).

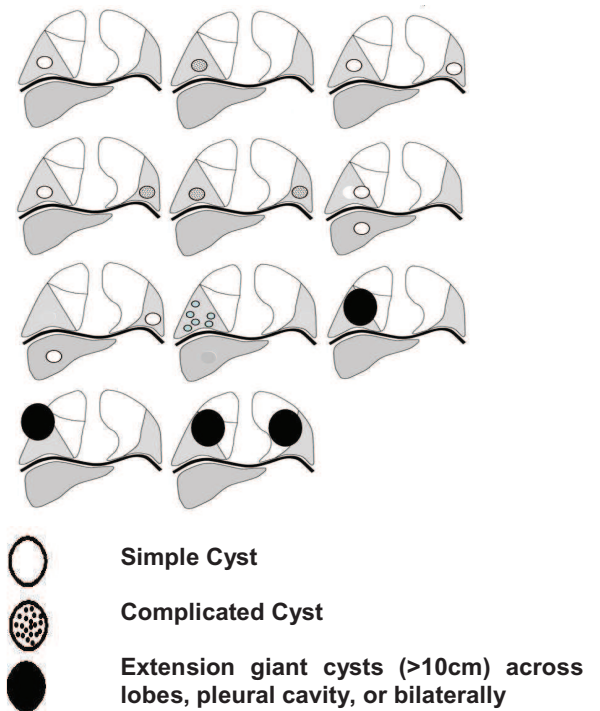


Figure 11: Sample of varying presentations of pulmonary hydatid cysts.

Anesthetic techniques usually require one lung ventilation with a double lumen endotracheal tube (DLT), or a bronchial blocker. This is especially helpful for complicated cysts, or bilateral cysts, to mitigate intra-bronchial spillage, aspiration, or contamination, especially in the lower lobes¹⁸. However, double lumen tubes or bronchial blockers can be difficult to place in children, and are not routinely used in our patients. Other disadvantages of DLT include misplacement, hypoxemia related to unilateral lung collapse or positioning, and traumatic intubation injury to the trachea or bronchus on intubation. Our routine in children is to employ single lumen endotracheal intubation for simple, non-infected cysts, and reserve DLT's for adolescents with large or infected cysts (complicated).

Access for open procedures include: anterior thoracotomy, posterolateral thoracotomy, simultaneous bilateral thoracotomy, bilateral trans-sternal thoracotomy, median sternotomy, staged bilateral thoracotomy, right transdiaphragmatic approach to the liver, and video assisted thoracoscopic surgery (VATS).

A number of surgical techniques have been described and advocated^{19,23}. These include:

1. Enucleation (intact endocystectomy- Ugon or Barrett's technique)

This procedure is performed with or without aspiration/injection of scolical agent^{5,6,7,11,19,20}. If >5cm, the cyst is aspirated, injected with scolical agent, then reaspirated (15-30 minute dwell time). Then dissection of the visceral pleura from the adventia or pericyst is performed. The operative field is protected with scolical soaked sterile sponges. A cruciate incision is made over the underlying endocyst. Careful enucleation of the intact cyst is then performed. The cavity is then cleaned and all identified bronchial leaks oversewn with figure of eight sutures. The cavity is left open if small and peripheral. Otherwise capitonnage is performed.

2. Cystotomy/ Cystectomy with or without capitonnage

Cystectomy involves removal of the cyst structure that includes the laminated and germinative layers encompassing the cyst content. The host reaction adventitia or pericyst layer is retained. Capitonnage is the term for closer or obliteration of the residual cavity. After cleansing of the cavity with 10-20% hypertonic saline soaked sponges, the bronchial leaks are closed with non-absorbable polypropylene, catgut, or coated polyglactin suture. Small peripheral cyst cavities do not usually require closure or capitonnage. Finally, a two layer method with suture closure of pericystic adventitial walls is followed, then horizontal mattress sutures obliterate the cavity, Capitonnage of deep cysts must avoid potential distortion of the remaining lobe, and avoid potential dead spaces. This procedure is commonly performed for large, deep and complicated (ruptured or infected) cysts.

3. Pericystectomy with or without capitonnage (Perez-Fontana technique)^{5,6,22}

This is an extended operation that removes the adventia or pericyst as well. There are no defined margins, and parenchymal lung remains to be repaired or obliterated with capitonnage, so as to control bleeding and air leaks. This is a more complex procedure.

4. Combined approaches for lung and liver cysts

Following treatment of the lung cyst a phrenotomy or transdiaphragmatic resection of the liver cyst is performed over the right hepatic dome^{19,20}. Liver cysts are different, insofar as they contain more daughter vesicles, and require scolical agents for local control. Via a lower right

thoracotomy through the 8th or 9th interspace, the diaphragm is exposed. The scolical agent is injected into the cyst that is palpated over the diaphragm. The diaphragm and cyst are opened. The daughter cysts or vesicles are aspirated or removed with spatula. A latex drain is placed in the cavity and exited out the side below the diaphragm. The cyst edges are marsupialized along the borders to the adjacent diaphragmatic edges.

5. Lung resection includes wedge resection, segmentectomy, lobectomy, or pneumonectomy^{5,6,15}

Less than 10% of children require resection for simple cysts vs. > 20% for complicated cysts. If > 50% of the lobe is involved then resection is recommended. **Balcic et al.**¹⁵, in a group of 63 children, noted a higher resection rate with ruptured or complicated cysts (6.3% wedge, 3% segment, and 12.7% lobectomy). **Dincer et al.**¹⁶, in a series of 44 children, reported an incidence of 16% lung resection as opposed to 5% in adults. This was due, in part, to a higher incidence of advanced disease in their pediatric patients, and a mean cyst diameter of 11.6cm.

6. VATS.

VATS has not been widely performed for hydatid cystic disease, given the concern for potential cyst rupture and allergic reaction contamination during or following the procedure²³.

Specific Concerns

Ongoing surgical concerns include: the use of scolical agents, massive hemoptysis; complicated cysts; giant cysts (>10cm); capitonnage; one stage vs. 2 stage approach for bilateral disease; lung with associated liver cyst; extension of cysts to pleural and extrapulmonary locations; and the future role of VATS.

A number of scolical agents have been utilized to prevent anaphylaxis during surgery⁴. They include: 10-30% hypertonic saline, 0.5% silver nitrate, 1-3% hydrogen peroxide, 1.5% centrimide-0.15% chlorhexidine, 40% centrimide, 70-95% ethyl alcohol, 1% formaline in 0.9% saline, 10% polyvinylpyrrolidone-iodine, and 10% diluted povidone-iodine. We prefer saline since it doesn't impair tissue healing. The injected dwell time ranges 20-30 minutes prior to reaspiration. Intraoperative cyst rupture or leakage can cause a severe allergic reaction, as well as seeding of daughter cysts in adjacent structures. Severe anaphylaxis can occur, but is rare. Recognition

and immediate treatment with epinephrine and supportive measures is crucial.

Massive hemoptysis in children is rarely caused by hydatid cysts, and is usually caused by erosion into a branch pulmonary or bronchial vessels²⁴. In the presence of an infected or complicated cyst resection is the treatment of choice, given lung sparing is not an option.

Complicated cysts with rupture into the bronchus or pleura have an increased incidence of morbidity and mortality, as well as requiring more extensive surgery and longer hospital stay²⁵. This justifies a more aggressive approach to earlier recognition and surgical treatment.

Giant cysts are usually defined as >10cm in diameter^{26,27}. The incidence is higher in children given the increased elasticity of lung parenchyma allows more rapid growth. They occur more commonly in the right lower lobe. Surprisingly, they are treated effectively with conservative cystectomy and capitonnage. Adjacent atelectatic compressed lung expands to obliterate dead space, thus decreasing the need for lung resection (6-13%)²⁶. When recognized, early surgery is recommended to decrease the incidence of spontaneous rupture with resultant contamination and possible anaphylaxis.

There is continued debate regarding the necessity of capitonnage, i.e. obliteration of the residual cavity with circumferential pursestring suture, or imbricating reefing sutures^{28,29}. **Delbet** first described capitonnage in 1899 as an infolding of the adventitia or pericyst to obliterate the cavity following cyst removal. **Crausaz** in 1967 described the evolution of this procedure to the placement of circumferential sutures from the base upward to obliterate the space or cavity²⁸. The major advantage of this technique is to avoid a residual cavity as a focus for infection, as well as preventing air leaks from residual bronchial fistulae. A disadvantage is lung distortion and residual atelectasis²⁹.

A one stage versus two stage operation have been recommended for bilateral cysts. Unilateral cysts are more common in pediatric patients. However, with bilateral cysts, a staged thoracotomy is our preference. Other approaches include a single stage operation via a bilateral thoracotomy or median sternotomy approach^{13,30,31}. **Lone et al.**³⁰ recommend a bilateral less invasive approach. This involves a supine position and bilateral small anterior thoracotomy (405 cm) through the 5th intercostal space. This approach is suitable for small simple cysts located more anteriorly. Posterior cysts, especially on the left, are more difficult to reach.

The median sternotomy approach to bilateral hydatid cysts has been reported by several groups, and primarily in adults. **Petrov et al.**³¹ reported excellent results via this approach in 82 patients. They caution that this approach is unsuitable for large infected cysts, pleural involvement with empyema or adhesions, and patients with severe comorbidity. Some suggest that concomitant abdominal cysts can be approached with extension of the median sternotomy incision.

A one stage operation for lung and an associated liver cyst has also been described^{19,32-36}. We prefer to refer the abdominal hydatid cysts to the pediatric surgeons following the thoracic procedure at the same sitting or later. They are approached via an endoscopic or open procedure. **Kurul et al.**³² from Turkey have reported a large series of 405 patients with right lung and right subdiaphragmatic liver dome cysts. Other deeper or lower liver cysts were referred to general surgery. Following resection of the lung cyst the diaphragm was opened over the dome cyst. Aspiration and cystotomy was performed. All bile leaks were sutured, then the liver pericyst was inverted with sutures to obliterate the cyst cavity. A subdiaphragmatic latex drain was placed. Placement of an omental flap into the residual liver cavity has also been described³³.

Extrapulmonary or intrathoracic cysts are defined as primary cysts not involved with pulmonary parenchyma, nor an extension of an abdominal process³⁹. They require an individualized approach. They can involve the pleura, pericardium, mediastinal structures, or the heart. Yet pleural complications of hydatid cysts can occur more commonly with rupture of a parenchymal lung cyst into the pleural cavity or erosion of a liver cyst into the thoracic cavity³⁷⁻⁴⁰. Concomitant decortication for empyema is usually performed for superficial parenchymal cysts that rupture into the pleural space. Local extension of pulmonary cysts into the pericardial cavity, pulmonary artery or chest wall are less common. Thoracic rupture of liver cysts with resultant empyema or broncho-biliary fistula require an aggressive complex surgical approach⁴⁰.

A classification of bronchobiliary fistulae has been established. Primary cardiac cysts has not been discussed.

The role of VATS for hydatid cysts has not been well defined^{23,41-44}. The advantage of a less invasive approach must be balanced with the risk of contamination and incomplete resection and control of bronchial fistula. Simple and small peripheral cysts are more suitable with this approach.

The major postoperative outcomes of surgery include mortality (0-2%), morbidity (3.5-27%), and cure (> 98%)²⁷. These are related to the extent of disease, and the operative procedures performed. Bleeding, atelectasis, lung collapse, persistent air leak, empyema, and wound infection are the early complications. Recurrence, or failure to eradicate the disease, is the major long-term complication and concern. Recurrence can occur from exogenous reinfection, or endogenous reinfection from incomplete surgical extirpation¹¹.

Table 2: Summarizes a contemporary series of pediatric patients treated surgically.

	Mortality	(%)	Morbidity	(%)
Elburjo, Libya (10)	1995, 43	0	NA	1
Rebhandl, Austria(11)	1999, 33	0	42.4	2
Celik, Turkey(12)	2000, 122	0	4	1
Topcu, Turkey(13)	2000, 128	0	15.6	1
Cangir, Turkey(14)	2001, 33	NA	NA	1
Balci, Turkey(15)	2002, 63	4.7	25.4	NA
Dincer, Turkey(16)	2006, 44	4.5	13.6	4.5%

In summary, our surgical approach is not to routinely aspirate simple and solitary non-infected intact cysts. For infected or complex cysts, these maneuvers are also not performed, given that infection has already destroyed the active cyst contents. Lung sparing is performed whenever feasible. Pleural adhesions are lysed, the involved lung and inferior pulmonary ligament mobilized, and identification/localization of the cyst by direct observation or palpation. Rarely, for larger intact cysts, aspiration is performed. Prior to aspiration or opening the cyst, the area is surrounded with soaked 10% saline packs/sponges. Then 20cc of hypertonic 20% normal saline is injected, followed by re-aspiration. Then the cyst is opened. A hypertonic saline soaked sponge is placed into the cavity to clean and debride. Identified bronchial leaks are closed with interrupted polypropylene (Prolene) or polyglactin (Vicryl, Ethicon) suture. The redundant adventitial or pericystic wall is excised. The cavity is left open if small or peripheral. Otherwise capitonnage is performed, if large or deep. The adventitia or pericyst layers are then closed primarily over the capitonnage. Two chest tubes are placed to drain the anterior and posterior chest space, and attached to low suction under water seal drainage. They are removed following

full lung expansion on CXR, and no air leak at 24 - 48 hours.

For complicated cysts ABZ treatment is usually continued in cycles of 28 days for 1 week-3 months in doses of 10-14mgs/kg/day with 14 day rest period between cycles⁵. Liver function tests are monitored. Broad spectrum antibiotics are given in selected situations that include contaminated cysts with positive bacterial operative cultures. With bilateral cysts, the 2nd stage operation is performed at 10-14 days following the first stage procedure. If the liver is involved, then an open abdominal or laparoscopic surgery is done concomitantly by the pediatric surgery team **Topcu et al.**¹³ present a reasonable algorithm for pediatric pulmonary hydatid cysts (figure 12) at the second stage chest procedure.

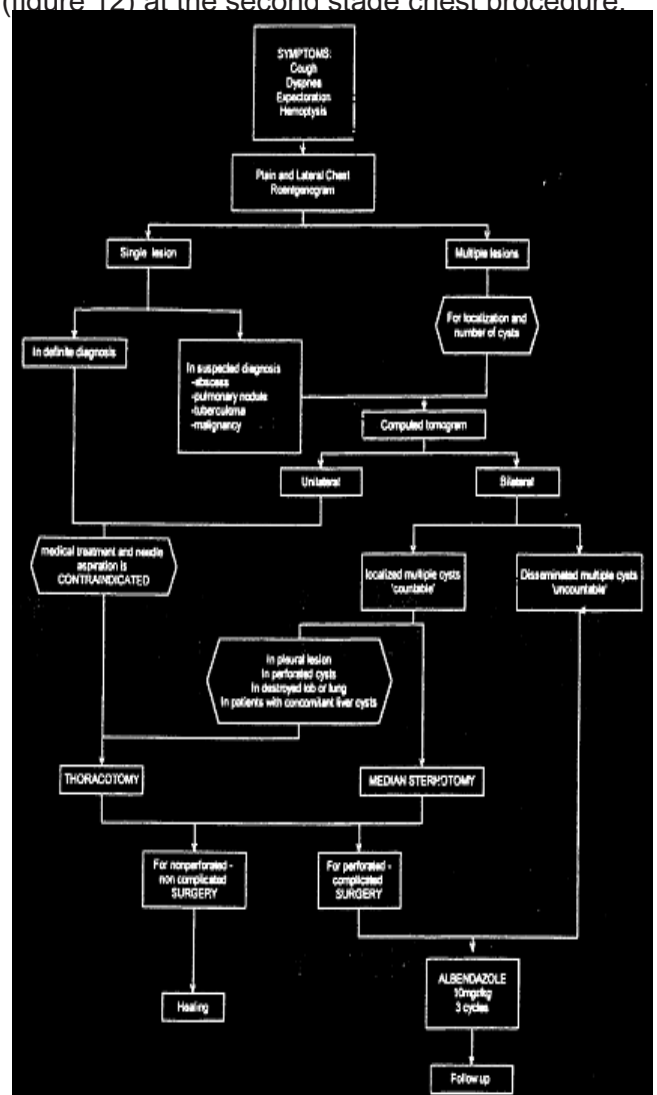


Figure 12: Treatment algorithm for pulmonary hydatid disease

Transdiaphragmatic procedures are not routinely done. Our approach differs somewhat in that we favor a staged thoracotomy for bilateral cysts, vs. the one stage median sternotomy approach.

References

- 1- Eckert J., Deplazes M. Biological, epidemiological, and clinical aspects of Echinococcosis, a zoonosis of increasing concern. *Clinical Microbiology Reviews* 2004;17:107-135
- 2- Eckert J., Gemmell MA., Meslin FX., Pawlowski ZS. WHO/OIE Manual on Echinococcus in Humans and Animals: a public health problem of global concern. <http://whqlibdoc.who.int/publications/2001/929044522X.pdf>. Accessed January 8, 2011.
- 3- Varela A., Burgos R., Castedo E. Parasitic diseases of the lung and pleura. In: Patterson GA, Cooper JD, Deslauriers J, Lerut AEMR, Luketich JD, Rice TW. Editors. *Pearson's Thoracic and Esophageal Surgery*. Churchill Livingstone/ Elsevier. Philadelphia, PA. 2008. P. 550-565
- 4- Auldist AW., Blakelock R. Pulmonary hydatid disease. In: Parikh DH et al. editors. *Pediatric Thoracic Surgery*. Springer-Verlag. London, UK. 2009. P. 161-167
5. Ramos G., Orduna A., Garcia-Yuste M. Hydatid cyst of the lung: Diagnosis and treatment. *World J Surg* 2001; 25:46-57
6. Harlaftis NN, Aletras HA, Symbas PN. Hydatid disease of the lung. In: Shields TW, Locicero J, Reed CE, Feins RH, editors. *General Thoracic Surgery Volume I, 7th ed.* Wolters Kluwer/Lippincott Williams & Wilkins, Philadelphia, PA. 2009; P.1187-1195
- 7- Moghissi K. Thoracic hydatid disease. In: Moghissi K, Thorpe JAC, Ciulli F. editors. *Moghissi's Essentials of Thoracic and Cardiac Surgery*. Elsevier Science. 2003; P.105-108
- 8- Keramidis D, Mavridis G, Soutis M, Passalidis A. Medical treatment of pulmonary hydatidosis: Complications and surgical management. *Pediatr Surg Int* 2004; 19:774-776
- 9- Kurkcuoglu IC, Eroglu A, Karaoglanoglu N, Polar P Complications of albendazole treatment in hydatid cyst of lung. *Eur J Cardio-thorac Surg* 2002; 22:649-650
- 10- Elburjo M, Gani EA. Surgical management of pulmonary hydatid cysts in children. *Thorax* 1995; 50:396-398
- 11- Rebhandl W, Turnbull J, Felberbauer FX, et al. Pulmonary Echinococcosis (Hydatidosis) in children: Results of surgical treatment. *Pediatric Pulmonol* 1999; 27:336-340
- 12- Celik BM, Senol C, Keles M, et al. Surgical treatment of pulmonary hydatid disease in children: Report of 122 cases. *J Pediatr Surg* 2000; 35:1710-1713
- 13- Topcu S., Kurul IC., Tastepe I., Bozkurt D., Gulhan E., Cetin G. Surgical treatment of pulmonary hydatid cysts in children. *J Thorac Cardiovasc Surg* 2000; 120:1097-1101
- 14- Cangir BA., Sahin E., Enon S., et al. Surgical treatment of pulmonary hydatid cysts in children. *J Pediatr Surg* 2001; 36:917-920
- 15- Balci AE., Eren N., Eren S., Ulku R. Ruptured hydatid cysts of the lung: Clinical review and results of surgery. *Ann Thorac Surg* 2002; 74:889-892
- 16- Dincer SI., Demir A., Sayar A., Gunluoglu MZ., Kara HV., Gurses A. Surgical treatment of pulmonary hydatid disease: a comparison of children and adults. *J Pediatr Surg* 2006; 41: 1230-1236
- 17- Guidelines for treatment of cystic and alveolar echinococcosis in humans. WHO Informal Working Group on Echinococcosis. *Bull World Health Organ* 1996; 74:231-242
- 18- Esme H., Fidan H., Cekirdekci A. The problems and advantages of one lung ventilation during surgical intervention in pulmonary hydatid cyst disease. *Ind J Thorac Cardiovasc Surg* 2006; 22:137-140
- 19- Athanassiadi K., Kalavrouziotis G., Loutsidis A., Bellenis I., Exarchos N. Surgical treatment of echinococcosis by a transthoracic approach: a review of 85 cases. *Eur J Cardio-thorac Surg* 1998; 14:134-140
- 20- Halezeroglu S. Resection of intrathoracic and subdiaphragmatic hydatid cysts. *Multimedia Manual of Cardiothoracic Surgery*. <http://mmcts.ctsnetjournals.org/cgi/content/full/2005/0425/mmcts.2004.000307> Accessed 12/08/2008
- 21- Al-amran FGY. Surgical experience of 825 patients with thoracic hydatidosis in Iraq. *Ind J Thorac Cardiovasc Surg* 2008; 24:124-128.
- 22- Burgos R., Varela A., Castedo E., et al. Pulmonary hydatidosis: surgical treatment and follow-up of 240 cases. *Eur J Cardio-thorac Surg* 1999; 16:628-635
- 23- Mallick MS., Al-Qahtani A., Al-Saadi MM., Al-Boukai AAA. Thoracoscopic treatment of pulmonary hydatid cyst in a child. *J Pediatr Surg* 2005; 40:E35-E37
- 24- Sing S., Vimesh P., Nadeem A. Massive hemoptysis in children- Unusual presentation in pulmonary hydatid disease.