

Introduction

Congenital heart diseases (CHD) are made up of structural or functional heart, defects which are present from birth and give rise to disease as growth takes place. The worldwide prevalence of CHD is 8-10/1000 live births; among these, 33% to 50% of such defects may be considered critical: they normally require intervention within the same hospital admission, and ideally, are dealt with early on during the first year of life. In locations across the globe in which healthcare resources are poor, several related and unrelated issues may prevent diagnosis and treatment being available to those children in an adequate time period:

1. Poor ante-natal performance during pregnancy;
2. Malnutrition;
3. Medications, alcohol, recreational drugs and smoking history during pregnancy leading to co-existing morbidities
4. (Frequent) late presentation of CHD beyond infancy;
5. Lack of early referral;
6. Illiteracy of the parents;
7. Large numbers of births taking place within homes lacking adequate sanitation;
8. Large numbers of births that are unsupervised by a doctor familiar with neonatal care;
9. Inadequate number of cardiologists and cardiac surgeons;
10. Lack of regional specialized cardiac centers;
11. Limited understanding and knowledge of CHD by local primary health care providers (physician, pediatrician, internist, etc.)

To overcome these obstacles the optimal strategy should involve the training and education of the local teams. Thus, a review of the essentials for the treatment of the most prevalent CHD is presented in following sections.

A: Understanding congenital heart diseases

Measurement of oxygen saturation by clinical observation and bedside pulse oxygenation testing, assists separation of congenital heart diseases into two main categories:

1- Acyanotic CHD: included in this category are children with near normal or normal arterial oxygen saturation shortly after birth.

Examples: Some ventricular septal defects (VSD), atrial septal defect (ASD), patent ductus arteriosus (PDA), coarctation of aorta, moderate pulmonary stenosis, and some mild cases that

belong to the spectrum of Tetralogy of Fallot.

2- Cyanotic CHD: In this category are those with clearly reduced arterial oxygen saturation that does not improve.

Examples: Tetralogy of Fallot (TOF), transposition of great arteries, tricuspid atresia, truncus arteriosus, total anomalous pulmonary venous drainage, hypoplastic left or right heart, and certain peri-natal cardiac tumors

B: Basics of Surgery for Congenital Heart Diseases

According to the clinical presentation, the surgical treatment of CHD can be grouped into two main **approaches:**

- 1- Palliative Procedures (staged)
- 2- Complete Repair (primary, definitive operation)

As a surgical program grows and becomes more established, some of the techniques described below may be modified as experience develops, and from personal choice and preferences of individual surgeons.

1.1. Palliative Procedures for Congenital Cardiac Lesions

A palliative operation is chosen to produce an improvement on abnormal circulation and heart function, minimize some of the anatomical and functional features of the disorder and worsening of abnormal growth; it is usually performed in children who are considered to be too young for corrective surgery at the regional center dealing with complex pediatric heart disease. The goal is to lessen cyanosis, control heart failure and prepare the circulation for later correction, anticipating natural growth. Each procedure is chosen to bring relief of symptoms, improvement in regional blood flow, and better oxygenation. The success of such operation is influenced by the child's growth, and absence of co-morbidities (and new onset diseases that commonly occur in most children).

It is anticipated that as the infant grows, age and body weight development indices will then permit a fully corrective surgical technique to be employed. The objectives in performing a palliative procedure are:

- a] To provide symptomatic relief;
- b] Allow the impact of the cardiac malformation to be better tolerated;
- c] Produce an improvement in the patient's general clinical condition.

A reduction in degree of cyanosis and improved hemodynamics usually produce a lowering in resting respiratory rate and effort of breathing, which leads to better food intake. A growth spurt may therefore be achieved during the interval before the child undergoes complete repair.

In the twentieth century, two classic palliative procedures emerged during development of neonatal and pediatric cardiac surgery procedures which are performed in clinical practice. Since their inception, modifications to the surgical technique have evolved:

Aortopulmonary shunt:

This procedure aims to directly connect blood from the ascending aorta or its branches to the pulmonary artery at the point distal to any obstruction: the operation is designed to increase pulmonary blood flow and promote an enlarge-

Pulmonary artery banding

In this scenario, pulmonary blood flow is excessive due to the intra-cardiac lesion, and if untreated, flooding of the pulmonary circulation will allow pulmonary hypertensive changes to occur. This operation is designed to carefully reduce pulmonary blood flow and pressure thereby protecting the pulmonary vasculature from progression towards irreversible pulmonary vascular disease. Multiple or large VSDs in infants weighting less than 3kg may present so, and the improvement in pulmonary dynamics and drop in respiratory rate may assist with better feeding, particularly at the breast.

More complex palliative procedures including the staging for the Norwood operation for hypoplastic left heart syndrome and the Glenn operation are outside the scope of this review.

Indications and timing of palliative procedures:

Aortopulmonary shunt

Most patients with pulmonary obstruction, presenting with cyanosis, dyspnea, and/or failure to thrive, usually benefit from a shunt procedure. This is a frequent operative choice in centers with limited experience, facilitates or support staff, and/or when the patient may be judged as too small for adequate total repair. Examples are Tetralogy of Fallot less than 3 months of age; and Pulmonary Atresia with or without VSD.

Surgical techniques

An aortopulmonary shunt can be performed through a mid-line sternotomy or through a right

ment in vessel size, as seen on the figure 1. e.g.: TOF and pulmonary atresia.

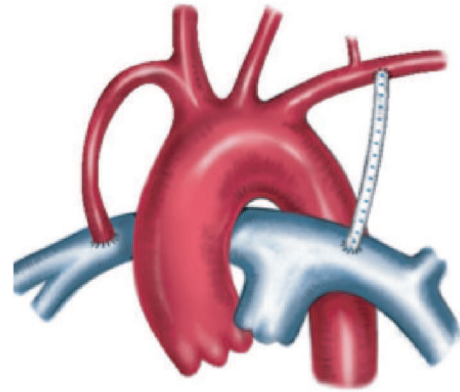


Figure 1- Aortopulmonary shunts: classic and modified Blalock-Taussig shunt

or left thoracotomy using one of the techniques described below:

I- Classic Blalock-Taussig-Thomas shunt:

This technique is now less commonly used. It consists of anastomosing the subclavian artery to the pulmonary artery on the side opposite the aortic arch.

With certain surgical technical modifications, the subclavian artery can be anastomosed to the pulmonary artery on the same side of aortic arch. The surgical approach is usually carried out through an upper thoracotomy centered on the upper border of the 3rd or 4th intercostal space. Among the essential surgical instruments are a straight and curved (Cooley) vascular clamps to permit uncluttered surgical access and retain hemostatic control throughout. A surgical headlight is also required. If performed on the left, careful attention must be given to avoid strenuous retraction of the left lung against the heart, which may produce poor venous return (Figure 2).

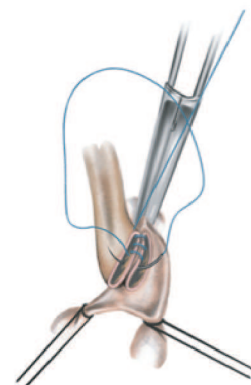


Figure 2- Classic Blalock-Taussig-Thomas shunt

II- Modified Blalock-Taussig-Thomas shunt (MBT Shunt)

In this procedure, a polytetrafluoroethylene (PTFE) tube graft (3-5mm, depending on age at presentation) is interposed between the subclavian or innominate artery and the right or left pulmonary artery using the same left or right thoracotomy access as described above. The surgical procedure requires the surgeon to apply careful judgment of the length of the graft chosen to provide sufficient flow, avoid kinking of the graft (too long) or puckering of the native vessels (too short) as the child grows during the “surgical interval” between operations. It is the most com-

monly performed shunt procedure (Figure 3).

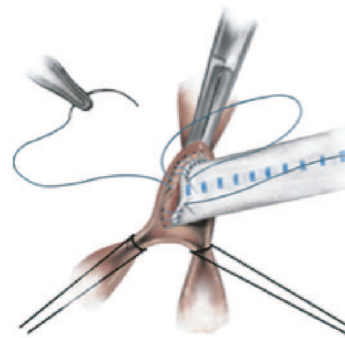


Figure 3- Modified Blalock-Taussig-Thomas shunt

2.1. Complete Repair of Congenital Cardiac Lesions

A Complete repair is feasible in many extra-cardiac as well as intra-cardiac congenital anomalies.

A- *Repair of extra-cardiac lesions:*

In these presentations, there is usually no need for cardiopulmonary bypass. The commonest examples are PDA, and coarctation of aorta.

PDA :

A spontaneous closure can be reasonably expected in small PDAs in full term babies at the age of 3 months; however, large PDAs are unlikely to close.

The timing for PDA closure is as follows:

- **Large/ moderate PDA, with congestive heart failure (CHF) and/or pulmonary hypertension (PAH):** Early closure (by 3-6 months) is recommended.
- **Moderate PDA, no Congestive Heart Failure (CHF):** closure at 6 months-1 year of age. If the infant is exhibiting failure to thrive, closure can be accomplished earlier.
- **Small PDA:** closure can be carried out at 12-18 months of life.
- **Silent PDA:** Closure is not recommended.

This entity is defined as a small ductus arteriosus with normal pulmonary artery pressure which cannot be identified clinically, except by Doppler echocardiography.

Coarctation of aorta

Surgical treatment currently represents the preferred option for the correction of coarctation of aorta (CoAo).

The defect is best approached through a limited left posterolateral thoracotomy based on the upper boarder of the 4th interspace, and is usually divided between clamps or ligated (Figures 4a and 4b) taking care to avoid the phrenic nerve and Abott's artery. If ligation only is chosen, the separate ligating sutures should be 2/0 or 3/0, carefully tied without subtraction to avoid “cheese-cutting” the friable duct, pulling on the vessel or worse, causing tearing off from the pulmonary artery or aorta. The surgeon should be prepared to immediately open the adjacent pericardium in that scenario to retrieve the retracted PA segment.

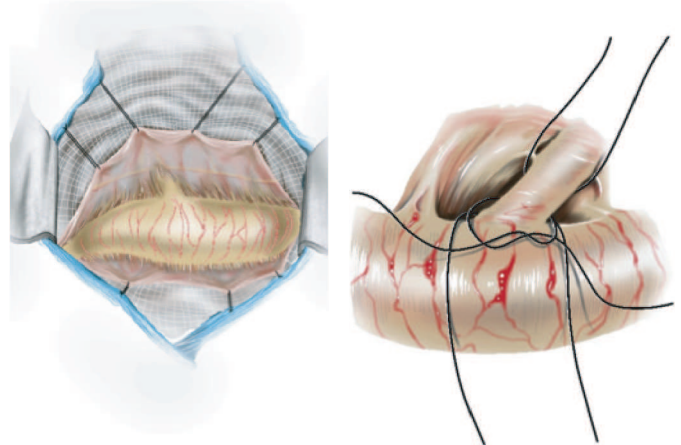


Figure 4a – PDA: surgical view Figure 4b – PDA ligation

The timing of intervention should be based on the clinical status at presentation, rather than waiting for developing hypertension and left ventricle dysfunction:

- Low gradient: Intervention is not indicated if Doppler gradient across coarct segment is <20 mmHg with normal LV function. It should be reassessed at regular intervals as the child grows and blood pressure measurements should be taken from right, left arms and one leg. Pulse delay should be checked and recorded if found.

- CoAo with LV dysfunction / CHF or severe upper limb hypertension (for age): Immediate intervention. In this scenario, considerable care should be taken during the operation to avoid retraction of the lung against the pericardium (which may produce a reduction in left atrial filling and subsequent bradycardia).

- CoAo with normal LV function, no CHF and mild upper limb hypertension: Intervention may be undertaken beyond 3-6 months of age

- CoAo with no hypertension, no CHF, normal LV function: Intervention can be made at 1-2 years of age.

The defect is best approached through a left posterolateral thoracotomy centered on the upper border of the 3rd left interspace using one of the following techniques (if made lower, it is very difficult to apply the appropriate clamps and gain surgical access).

- resection and end-to-end anastomosis (Figure 5a and 5b),

- augmentation of the coarcted segment

B- Repair of intra-cardiac lesions:

These usually require cardiopulmonary bypass. The commonest defects are VSD, ASD, and Tetralogy of Fallot.

Atrial Septal Defect (ASD)

A spontaneous closure is rare if the defect is >8 mm at birth and if still evident after age 2 years.

The timing of repair is based on the symptomatology secondary to pulmonary blood overload, as follows. (If a child is well and the lesion is picked up by auscultation on routine review, many surgeons will choose to do this operation during school holidays or at parents' convenience. It is usually non-urgent):

- **Asymptomatic ASD:** These can be repaired at 2-4 years.

- Symptomatic ASD in infancy - CHF, severe Pulmonary Artery Hypertension (PAH): (8%-10% of cases). For these, early closure is recommended, and it should be fully confirmed that this is the only cardiac lesion present.

- **Late presenting ASD:** Elective closure should be carried out at presentation irrespective of age and, especially, if there is right heart volume overload and pulmonary vascular resistance

with subclavian flap, or synthetic patch -polytetrafluoroethylene (PTFE).

Note: Occasionally, it may be necessary to introduce one of the clamps through a lower intercostal space to gain a suitable clamp position. The use of silastic slings after careful, discrete (localized) dissection of the proximal and distal aortic segments is an important adjunct to the surgical technique.

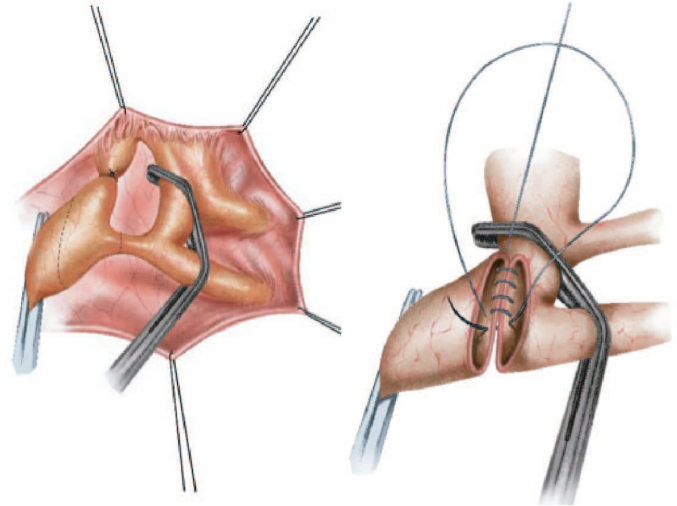


Figure 5a – Juxta-ductal coarctation of aorta. Figure 5b - End-to-end anastomosis of the coarcted segment.

(PVR) is within operable range (PVRIO<10WU. m2 – PVRIO. Pulmonary vascular resistance index can be assessed using a pure oxygen inhalation challenge).

ASD closure is most commonly approached through a median sternotomy under cardiopulmonary bypass. In centers with a large experience it is occasionally managed by upper right thoracotomy, centered on 4/5th interspace. This can be a helpful operative approach in girls who may seek to avoid a central chest scar. If the later procedure is done, very careful cannulation techniques must be used to avoid accidental line loss; the incision must not be placed anteriorly so to avoid risking a dimpling deformation of the right breast later on, when the patient reaches puberty.

An autologous pericardial patch is usually used to close the defect. (Figure 6a and 6b). If future surgery is anticipated for an additional cardiac lesion, it is best to also use commercial pericardial patches to then draw the pericardium closed, (if such materials are available). This is carried out on terminating cardiopulmonary by-pass and de-cannulation.

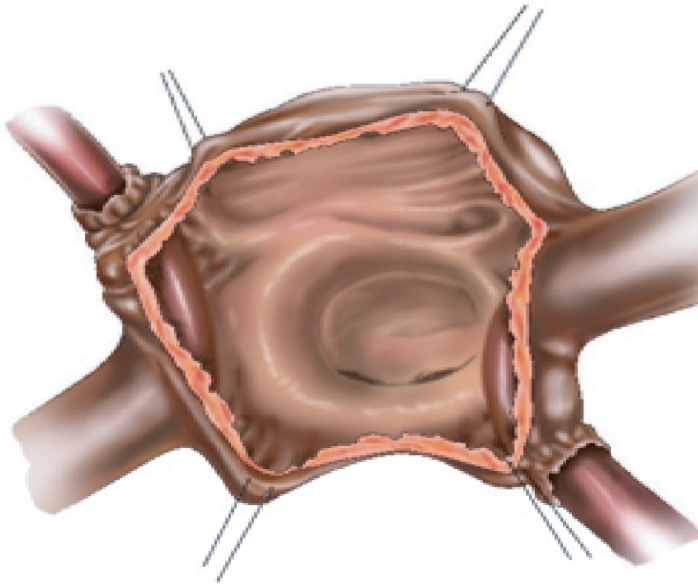


Figure 6a – Secundum ASD.

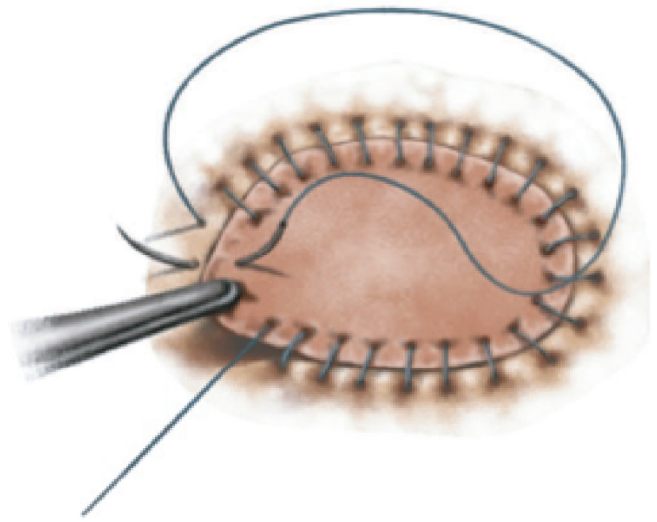


Figure 6b – ASD: patch repair

Ventricular Septal Defects (VSD)

Approximately 30%-40% of moderate or small defects (restrictive) close spontaneously, the majority closing by 3-5 years of age or becoming hemodynamically insignificant without shunt flow on serial echocardiographic assessments. Spontaneous closure is uncommon in large VSDs, some of which (approximately 10%) die in first year of life, primarily due to CHF when the VSD is large and non-restrictive (= diameter of the aortic orifice)

The timing of repair is based on the symptomatology characterized by the presence of CHF, respiratory infection and/or PAH. In those children presenting with cardiac or other comorbidities, a careful review of the peri-operative management in Intensive Care equipment, nursing skills and medications that are available should be made. Even after a perfect surgical result, in the OR, a child's most challenging time may be in the post-operative period.

Surgical technique

The VSD is approached through a median sternotomy under cardiopulmonary bypass and closure is accomplished by use of a pericardial patch, (autologous pericardium, Dacron patch or PTFE membrane are popular). (Figure 7a and 7b). Great care should be given in regard to

- **Large VSD with uncontrolled CHF:** Repair should be carried out as soon as possible, after accomplishing maximizing general hemodynamic improvement before the child undergoes anesthesia.
- **Large VSD with severe PAH:** Repair at 3-6 months.
- **Moderate VSD with PASP 50%-66% of systemic pressure:** Repair is recommended between 1-2 years of age or earlier if one episode of life-threatening lower respiratory tract infection or failure to thrive.
- **Small sized VSD with normal PAP, left to right shunt >1.5:1:** Closure by 2-4 years.
- **Small outlet VSD with any degree of aortic regurgitation (AR):** Surgery whenever AR is detected.
- **Small VSD with one previous episode of infective endocarditis:** Early VSD closure is recommended.

suture placement to avoid ensnaring one of the aortic cusp, conduction system, and deforming the tricuspid valve leading to valvular incompetence. Some surgeons do not use pledgets throughout. Some prefer a single, continuous suture technique.

This may suffer from the risk of rupture and un-zipping which can cause dynamic sub-aortic obstruction (and require emergent re-operation). A four-quadrant interval continuous technique reduces the probability of this complication occurring. Surgical approaches are now most commonly carried out by opening the right atrium and

gentle upward retraction of the septal cusp of the tricuspid valve, but some circumstances may require right ventriculotomy or, by direct access through an aortotomy/pulmonary truncal opening to gain access to the immediate sub-aortic or sub-pulmonary margin of the defect.

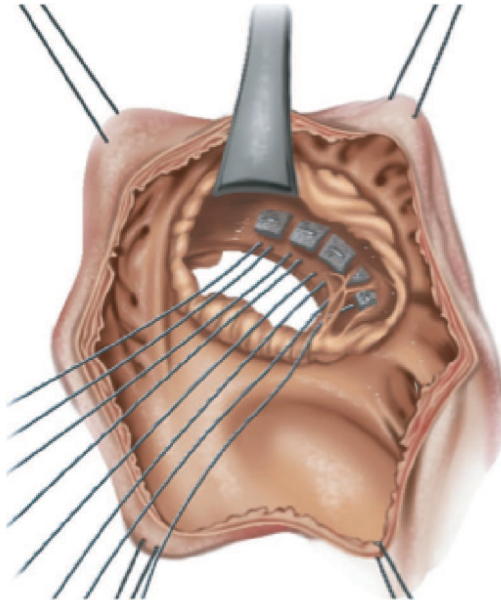


Figure 7a – Perimembranous VSD.

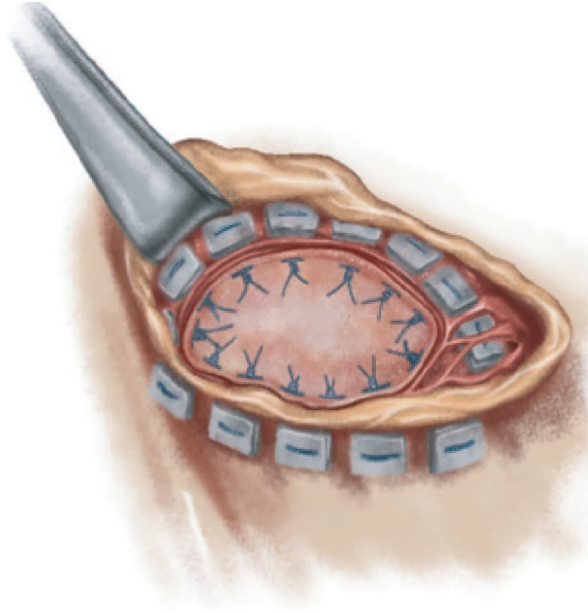


Figure 7b – VSD: patch repair.

Tetralogy of Fallot

This accounts for 15% of all cyanotic heart diseases. All patients need surgical repair but in patients coming from rural locations, the primary diagnosis may be sometimes delayed well into the patient's teen years.

The timing of repair is often based on the severity of cyanosis if the patients are seen soon after birth. They may require a different peri-operative strategy depending on factors relating to surgical and anesthetic perfusion and nursing experience, and the availability of specialist management, operative and perfusion equipment in such small sized patients.

1- **TOF stable, minimally cyanosed:** Total correction can be usually, safely carried out at 1-2 years of age or earlier according to the institutional policy.

2- **TOF with significant cyanosis ($SaO_2 < 70\%$) or spells despite therapy**

- **<3 months:** A BT shunt may be performed, scheduling full correction after a growth period.

- **>3 months:** shunt or correction depending on anatomy, growth, co-morbidities and surgical centers' experience

TOF is approached through a median sternotomy under cardiopulmonary bypass. The repair

consists of closure of VSD with a patch (usually bovine pericardium or Dacron patch) and augmentation of the RV outflow tract and the stenosed pulmonary valve and arteries (Figures 8a and 8b).

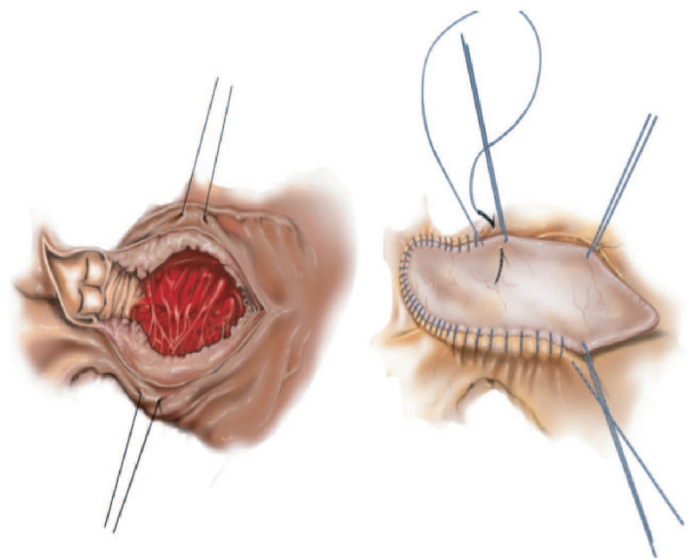


Figure 8a – RVOT obstruction: surgical view.

Figure 8b – RVOT: patch augmentation.

The results of surgery usually show substantial improvement in patient's tolerance to exercise, improved growth and resolution of cyanosis. Patients should be advised that there may be some distortion of the pulmonary artery following growth and that surgical revision may be required.

Summary

1. PDA, CoAo, ASD & VSD with their respective anatomic variants and the lesions found in TOF represent > 80% of all CHD for which a center that is located in a resource-poor environment may reasonably develop the capability to repair them
2. Pediatricians/ cardiologists/ other health care providers should strive to get a complete diagnosis on a child suspected of having heart disease, even if that requires referral to an advanced center.
3. Development of surgical protocols: these are vital tools to help with in pre-operative planning, peri-operative management; they also help provide a smooth passage through the essential features of management in each clinical presentation: diagnosis and surgical decision, the optimal timing of intervention. Such a strategy will help achieve good outcomes in the more common congenital heart diseases which present to resource-poor centers.

References

1. Working Group on Management of Congenital Heart Diseases in India. Consensus on Timing of Intervention for Common Congenital Heart Diseases. Indian Pediatrics. 45: 117-126, 2008. Guidelines
2. Shi-Min Yuan, Hua Jing. Palliative procedures for congenital heart defects Archives of Cardiovascular Disease. 102: 549—557, 2009. Review
3. Tchervenkov C, Jacobs JP, Bernier PL, Stellin G, Kurosawa H, Mavroudis C, Jonas RA et al. The improvement of care for paediatric and congenital cardiac disease across the World: a challenge for the World Society for Pediatric and Congenital Heart Surgery. Cardiology in the Young 19(Suppl. 2): 112–117, 2009.
4. Talwar S, Choudhary SK, Airan B, Juneja R, Kothari SS, Saxena A, Kumar AS. Reducing the costs of surgical correction of congenitally malformed hearts in developing countries. Cardiol Young 18: 363–371, 2008.
5. Brown KL. Socioeconomic status and outcomes of paediatric cardiac surgery. The Lancet Child & Adolescent Health, 2018. Available at:

4. Ongoing training of those involved in specialist pediatric care and collaboration with other centres in the region. There are three aspects of this essential practice:

- A] local team encouragement and support throughout the year so those entering the specialty for the first time are encouraged to continue. All team members (doctors, nurses, perfusionists, technicians, respiratory therapists, biomedical and other supporting staff) should be treated with equal respect as vital members.
- B] Regional collaboration should be fostered to share experience and care pathways with other emerging centres; colleagues must encourage each other and celebrate innovative and new techniques in overall clinical care; there should be general agreement that all should work hard to reduce any competitive activity which might lead to discouragement and/or failure.
- C] A database (e.g. The World Database) should be introduced into the program as soon as is possible to track and provide quality assurance standards that can be followed and guarded.

Acknowledgments

The authors would like to thank J.B. Bastos for his assistance in the illustrations of this manuscript.

- [https://doi.org/10.1016/S2352-4642\(18\)30134-26](https://doi.org/10.1016/S2352-4642(18)30134-26). ESC Guidelines for the management of grown-up congenital heart disease (new version 2010). European Heart Journal (2010) 31, 2915–2957.
7. Setty HSSN, Patil SSG, Ramegowda RT, Vijayalakshmi IB, Manjunath CN. Comprehensive Approach to Congenital Heart Defects. J Cardio-vasc Disease Res., 2017; 8(1): 1-5
 8. Linde D, Konings E E M, Slager MA, Witsenburg M, Helbing WA, Takkenberg JJM, Roos-Hesselink JW. Birth Prevalence of Congenital Heart Disease Worldwide: A Systematic Review and Meta-Analysis. J Am Coll Cardiol 2011; 58: 2241–7
 9. Hui-Li Gan, Jian-Qun Zhang, Qi-Wen Zhou, Lei Feng, Fei Chen, and Yi Yang. Patients with Congenital Systemic-to-Pulmonary Shunts and Increased Pulmonary Vascular Resistance: What Predicts Postoperative Survival? PLoS One. 2014; 9(1): e83976
 10. Fortescue EB, Lock JE, Galvin T, McElhinney DB. To close or not to close: the very small patent ductus arteriosus. Congenit Heart Dis. 2010 Jul-Aug; 5(4): 354-65.



CHIRURGIE VASCULAIRE / VASCULAR SURGERY

PRISE EN CHARGE DES VARICES DES MEMBRES INFERIEURS AU CENTRE HOSPITALIER UNIVERSITAIRE DE BRAZZAVILLE

ATIPO-GALLOYE R^{1,2}, KOMBO BAYONNE S³, NGROUND
MONIANGA S A², OKIEMY GODEFFROY²

- 1- Université Marien Nguabi, Faculté des Sciences de la Santé, Brazzaville
2-Service de chirurgie polyvalente, CHU de Brazzaville, BP 32 Brazzaville, Congo
3- Service de Dermatologie-maladies infectieuses, Hôpital de référence de Talangai, Brazzaville

Correspondance: Atipo-Galloye R

Université Marien Nguabi, Faculté des
Sciences de la Santé, Brazzaville Congo

Résumé

Objectif : Décrire les aspects épidémiologiques, cliniques, étiologiques et thérapeutiques des varices des membres inférieurs. **Patients/méthodes** : Il s'est agi d'une étude rétrospective, réalisée au CHU de Brazzaville, entre Mai 2016 et Juin 2018. Tous les patients ayant été opérés durant cette période pour varices, et dont le dossier médical comportait un compte-rendu opératoire ont été inclus. Les patients ont été répartis suivant la classification CEAP d'Hawaii 2004 modifiée. Les deux techniques opératoires employées ont été la chirurgie et la sclérothérapie, soit sous rachianesthésie ou sous anesthésie locale. Les variables analysées ont été : sociodémographiques, cliniques, étiologiques, et thérapeutiques. **Résultats** : Au total quarante cinq patients ont été opérés, avec un âge moyen de 42+/-2,5 ans, et un sexe ratio à 0,8. Plus de 90% de nos patients étaient symptomatiques avant la chirurgie. Le principal motif de consultation a été la lourdeur des membres inférieurs, et plus d'un quart de nos patients avaient consulté au stade C3. L'origine a été essentielle dans 55,5%, suivie des causes post thrombotiques dans 17,8%. Les veines superficielles ont été les plus touchées. Le mécanisme physiopathologique en a été le reflux dans 68,5%. Le geste le plus réalisé a été la ligature de la jonction sapheno-fémorale associée à un stripping et des phlebectomies chez vingt cinq patients. Deux cas de récives ont été rapportés après sclérothérapie. **Conclusion** : La prise en charge des varices dans notre contexte reste dominée par la chirurgie. L'adoption des nouvelles techniques endovasculaires permettrait d'en améliorer les résultats.

Mots clés : Varices, membres inférieurs, CHU de Brazzaville.